

# **Physical Therapy for Fractures and Orthopedic Disorders**

---

**Third Edition 2013**

**Prof. Shehab M. Abd El-Kader**

Professor of Physical Therapy

# **Cervical Spondylosis**

## **Definition**

Spondylosis: is a gradual progressive degenerative change in the intervertebral joints between the bodies and the discs and/ or osteoarthritic changes in the synovial facet joints of spine (apophyseal joints).Clinically: Both conditions often occur together.

## **Etiology**

There is no known cause of the spondylosis, but there are many predisposing factors:

- 1- Aging process: changes due to age leading to dehydration of the intervertebral discs.
- 2- Faulty posture associated with:      \* anxiety      \* bad habit.
- 3- Repeated minor trauma
- 4- Genetic weakness.
- 5- Occupational stress: Flexion of the neck for long time and
- 6- Carry weight on his head.

## **Incidence**

The most commonly affected area is C4 - T1: the most curved and the most mobile part of the cervical spine. Usually the patient is around 45years old. Women are more commonly affected than men. The type of person is often anxious and worrying by nature.

## **Pathology**

Degeneration of the disc: It begins within the annulus fibrosis in the form of slight tears of the annular fibers and cracks appear at various sites and as a result nuclear herniation through the torn annulus. Also, osteophytes formation and apophyseal joints (Facet Joints) osteoarthritis.

## **Manifestations**

They are determined according to the direction of osteophytes and tissues compressed by these osteophytes.

## **I. Local manifestations**

They occur due to compression of osteophytes upon posterior longitudinal ligament in the form of:

- Neck pain: due to mid-cervical pathology
- Localized tenderness: in paraspinal muscles.
- Restriction and limitation of neck ROM.

## **I. Radiculopathy**

Due to compression on sensory and/or motor nerve roots in the intervertebral foramina through osteophytes.

### **1) Sensory manifestations:**

The sensory manifestations are more than motor symptoms in the form of numbness, tingling and pain according to the dermatome: Radiating pain to the upper limb: shoulder girdle, shoulder and arm pain due to pathology from C4 to T1

- In the interscapular area (C5, C6)
- In the upper limb: C5 to C8
- In the thumb: C6
- In the ring, little fingers: C7, C8

The reason for this sensory involvement rather than motor deficit is that the nerve root normally divides into two distinct roots (50% of cases) at the neural foramina level. The sensory root lies in proximity to the posterior apophyseal joints and hence, encroachment upon this posterior (sensory) root leads to sensory manifestations rather than motor deficit. This explains why in EMG the motor manifestation is negative while the sensory conduction velocity is reduced.

### **2. Motor manifestations**

Neck muscles are often weak if there is pressure on a nerve root, there is will be weakness in the muscles (myotome) supplied by that root.

## **III. Myelopathy**

Due to posterior osteophytes that compress the cord at the cervical level especially if there is an additional spinal canal stenosis (< 14 mm). It may cause

1. Quadriparesis: in central or bilateral lesion.
2. Ipsilateral hemiparesis: in unilateral lesion, below the level of lesion.

## **VI. Cervical Headache**

It occurs especially due to compression of osteophytes on the upper cervical or with compression on the vertebralbasilar artery = vertebralbasilar artery insufficiency (affecting blood supply of the brain).

### **Radiography**

- Narrowing of the disc space.
- Osteophytes (lipping of the vertebral bodies).
- OA of the posterior apophyseal joints.
- Flattening of cervical lordosis.

### **Treatment**

#### **I. Medical**

1. Analgesics and anti-inflammatory drugs.
2. Muscle relaxant.
3. Tonics and multi-vitamins.

#### **II. Surgical**

Rarely only if there is a marked cord compression. So, Laminectomy with or without discectomy, anterior approach, removal of compression, followed by spinal fusion in multiple lesions.

#### **III. Physical therapy**

##### **Aims**

- 1- Relief local and/or radiated of pain
- 2- Inhibition of muscle spasm
- 3- Restoration of movement
- 4- Strengthening of the weak muscles.
- 5- Education of the posture.
- 6- Analysis of precipitating factors to reduce recurrence of the patient's problems.

- 7- Decrease compressive load on cervical discs to regain its fluid balance.
- 8- Improve V.B.I. and relieve headache (if present).

### **Methods of treatment**

**1- Heat:** Passive modalities generally involve the application of heat to the tissues in the cervical region, either by means of:

a- Superficial heat

- Dry heat: Infra red for 15 minutes.
- Moist heat: Hot packs for 20-30 minutes.

b- Deep heat

- Short wave: 15 minutes.
- Ultra-sound:  $1.5 \text{ watt/cm}^2$  for 5 minutes.

1. To reduce muscle spasm.
2. Improve circulation and nutrition.
3. Remove metabolites and waste products.

### **N.B.**

Patient should be in relaxed position during application of heat for 10 - 20 minutes once or twice a day during an acute episode.

### **2- Neck brace or collar**

Soft cervical collars are recommended for daytime use only, but they are unable to appreciably limit the motion of the cervical spine. More rigid orthoses (e.g., Philadelphia collar, Minerva body jacket) can significantly immobilize the cervical spine in severe acute stage only.

### **N.B.**

- A firm collar is used for sufficient length of time to assure diminution of inflammation, during traveling or work and should be removed during performing exercises and hot packs application.
- When the pain has subsided the collar should be taken off when the patient is resting. The periods without the collar should be gradually extended.
- Collar should not be used for a long time to avoid dependence, disuse, muscle weakness.

- Values of collar are to decrease the compressive load on the cervical vertebrae by transmitting the weight of the head to the clavicle and to reduce nerve irritation.
- A program of isometric cervical exercises may help to limit the loss of muscle tone that results from the use of more restrictive orthoses.

### **3. Manual therapy**

Manual therapy as therapeutic massage, mobilization, manipulation may provide further relief for patients with cervical spondylosis. Mobilization is characterized by the application of gentle pressure within or at the limits of normal motion, with the goal of increasing the ROM. Manual traction may be better tolerated than mechanical traction in some patients.

### **4. Cervical Traction**

Mechanical traction is useful as it promotes immobilization of the cervical region and widens the foraminal openings. Intermittent traction (oscillatory) is considered to be mobilizing, therefore is appropriate where the neck is generally stiff. It is useful for disc nutrition.

Continuous traction is used to relieve nerve root pressure. Also it is essential to ensure that the paravertebral muscles are relaxed and lengthened (e.g. by heat, hold-relax, passive stretching) prior to the application of traction. Traction is applied from supine lying position or sitting position, for 15 minutes. Weight must not exceed 7 % - 20 % of total body weight.

### **5. Movement**

The use of cervical exercises has been advocated in patients with cervical spondylosis. Isometric exercises often are beneficial to maintain strength of the neck muscles.

- Hold relax techniques (static only).
- Active neck movement within the available ROM, especially the oblique patterns.
- Active strengthening exercises of the shoulder girdle.

## **Advices**

### **1) Sleep:**

- a) In supine sleep: one pillow under the head.
- b) In side lying: 2 pillows to fill the gap between the neck and shoulder.

### **2) During the day:**

Avoid prolonged fixed position(s) of the neck especially flexion and rotation  $\pm$  lateral flexion. Every 30 minutes, the neck should be stretched and moved through the full ROM especially during the jobs that need sitting, reading, writing or car driving for long time.

### **3) Perform gentle active exercises daily for the neck muscles.**

### **4) Avoid watching television from sides.**

### **5) Avoid going backward by the car.**

### **6) Avoid holding telephone by shoulder.**

### **7) Avoid air draft and sleeping in cold weather.**

### **8) Hot packs** are applied on neck and spasmodic muscles at home 2 - 4 times, 20 - 30 minutes for each time.

## **Cervical Disc Lesion (Cervical Disc Herniation)**

### **Definition**

Cervical disc lesion means release of the nuclear material from the enveloping annulus fibrous capsule that is precipitated by wear and tear.

### **Causes**

There is a history of:

- 1- External trauma. Trauma may be auto accident or fall.
- 2- Prolonged abnormal posture.
- 3- Severe prolonged emotional tension.
- 4- Degeneration.

### **Manifestations**

- **Onset:** sudden severe neck pain.

- **Local manifestations:** Clinically the patient presents with

1. Protective neck muscle spasm.
2. Neck is fixed; usually slight side bending to the affected side, due to muscle spasm. All neck motion especially ipsilateral rotation is restricted (active and passive).

- **Radicular manifestations:**

1. Sensory compression causes referred pain, numbness, tingling to the affected dermatome.
2. Motor compression causes slight muscle weakness in the affected myotome.

### **Examination**

- 1- Guarding by the patient when moving the neck.
- 2- Assuming a protective neck posture; e.g. holding the head and neck to one side or avoiding extension.
- 3- Reproducing pain by the patient's active motion of the neck.
- 4- Passive neck motion initiates and aggravates pain.
- 5- With digital palpation of the foramina on either side of the neck, there is irritation of the entrapped nerve root this causes local pain, tenderness and radiation of pain in the dermatomal direction.



## **Investigations**

### **1. CT scanning.**

### **2. MRI.**

### **3- Plain X-ray.**

**4- Myelography:** It is an X-ray after injection of a dye in the spinal canal to detect the level of protrusion and the severity of protrusion.

## **Treatment of the cervical herniated disc**

### **I. Conservative treatment:**

#### **A) Acute stage (1<sup>st</sup> 3-4 weeks after injury)**

1. Rest
2. Hard collar or neck brace is preferable for immobilization of the neck.
3. Medications to relieve pain.
4. Low force traction for relieve of pain (manual traction).
5. In severe pain, all exercises can be postponed till improving of pain.

#### **B) Sub acute stage**

1. Release the collar or brace.
2. Heat application: US, IR.
3. Electrical stimulation: TENS to relieve pain
4. Deep friction, kneading massage.
5. Manipulation therapy → ↓ pain + ↑ ROM.
6. Traction must be continuous.
7. Stretching exercises.
8. Active free neck exercises.
9. Hold-relax techniques.
10. Gentle active progressive resistive exercises.
11. Posture exercises to correct: lordosis, forward head posture.
12. Shoulder girdle and upper limbs exercises.
13. No dynamic neck flexion exercises as it may lead to more prolapse of the disc.

### **II. Surgical Treatment**

It is indicated when the pressure from central disc herniation upon the spinal cord is associated with upper motor neuron signs and symptoms:

1. Positive Babinski.
2. Hyper reflexia.
3. Bowel or bladder dysfunction.
4. Neurogenic paralysis: paraplegia, or quadriplegia.
5. Functional impairment: An impairment or disability that is not tolerable or acceptable by the patient.

# **Frozen shoulder**

## **(Adhesive capsulitis, Periarthritis)**

### **Definition**

Adhesive capsulitis is a chronic capsular inflammation with fibrosis of the capsule of the glenohumeral joint. Adhesive capsulitis and frozen shoulder are two of the terms commonly used to describe a painful and stiff shoulder joint. It is of unknown etiology.

### **Types**

#### **1) Primary adhesive capsulitis**

It is idiopathic and spontaneous. An unknown stimulus creates histological changes in the joint capsule that are different from the changes caused by immobilization or aging.

#### **2) Secondary adhesive capsulitis**

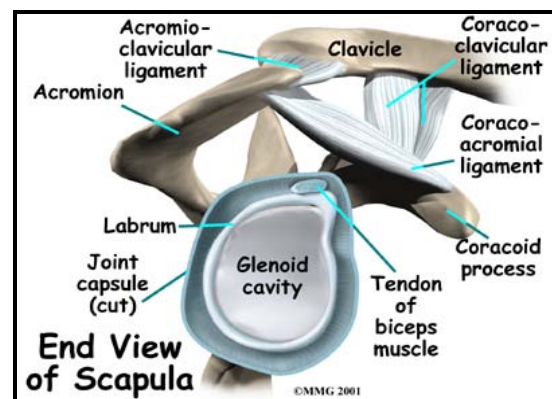
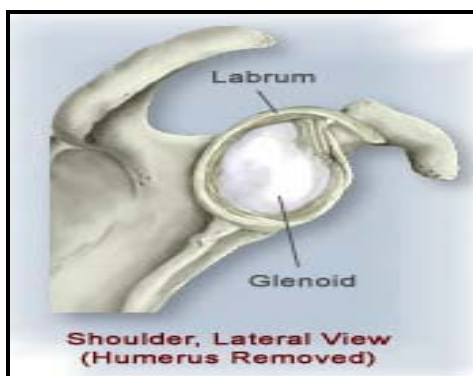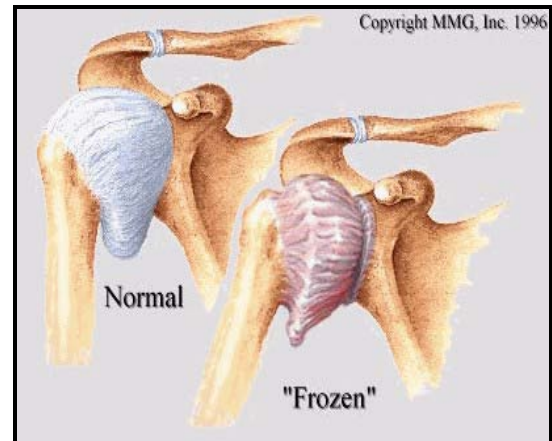
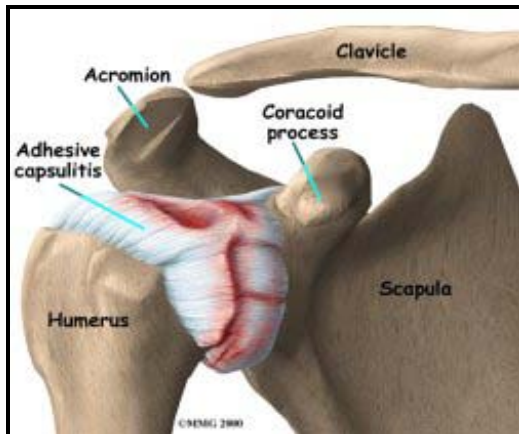
It is always preceded by an episode of trauma or immobilization (voluntary or involuntary), as a result of pain, soft tissue disorder around the joint or systemic disease (especially diabetes, hemiplegia).

### **Incidence of adhesive capsulitis**

- It is higher in females and persons in the age between 40-60 years.
- It develops more commonly in the non-dominant arm.

### **Pathology**

There is thickened and fibrotic glenohumeral capsule adherent to the humeral head and an obliteration of the capsular axillary pouch.



## Clinical Features (Manifestations)

### 1- Pain:

- Acute pain that is not relieved by rest.
- The pain is severe aching pain in the shoulder and upper arm.
- Pain is of gradual and spontaneous onset.
- Pain is usually the primary complaint during the first few weeks and can disturb sleep.

### 2- Painful movement

As the condition proceeds, pain at rest subsides. Painful movement becomes the primary complaint. Pain is usually diffuse over the deltoid and/or C5 dermatome.

### 3- Loss of motion

- There is uniform limitation of all shoulder movements.
- Loss of shoulder girdle motion.

- Tight and inelastic rotator cuff muscles due to chronic inflammation with fibrosis.
- There is mild wasting of the scapular muscles and tenderness may be felt below the acromion process and in front.
- Diminished function in the activities of daily living (as grooming, dressing).

#### **4- Course of the disease**

- There is a tendency towards slow spontaneous recovery, usually within 6-12 months.
- The pain subsides first leaving glenohumeral stiffness which gradually improves with the use of the limb.
- There are 3 distinct phases:
  - 1- Increasing pain and increasing stiffness.
  - 2- Decreasing pain with persistent stiffness
  - 3- Gradual return of movement.

#### **5- Objective Examination**

Findings vary with the stage or severity. The only finding is uniform impairment of all glenohumeral movements: abduction, flexion, extension and rotation, which are often reduced to  $\frac{1}{4}$  or  $\frac{1}{2}$  their normal ROM.

##### **In acute stage (severe case)**

- The patient exhibits guarded motion and protective muscle spasm during ROM testing (empty end feel).
- Shoulder movement that remains is contributed by scapular movement, which is unimpaired.

##### **In subacute stage**

- Motion restriction with a capsular end-feel predominates.
- The capsular pattern of restriction is external rotation, is more limited than abduction, which is more limited than internal rotation.
- Accessory motions are also limited, especially anterior and inferior glide of the gleno-humeral joint.
- Disuse atrophy may be present, however, resisted motions are generally strong and pain free.
- Despite the presence of pain in C5 dermatome, neurological tests are negative.

## **Investigations**

- Radiographs: are used to rule out other conditions. X-ray of the shoulder is normal.
- Arthrography(It is diagnostic)
  - \* There is a loss of glenohumeral joint capsule extensibility.
  - \* Normal joint volume capacity is 20 - 30 ml. The capacity of a patient with frozen shoulder is 5 - 10 ml.
  - \* There is loss of:
    - The axillary pouch
    - The subscapular bursa
    - The long head of biceps sheath.
  - \* It confirms a tight, thickened capsule. It provides no information about the type of onset or extent of recovery.

## **Treatment of Frozen Shoulder**

### **I- Conservative treatment**

#### **1) In acutely painful stage**

- a- The arm is rested in a sling, which is removed each day to permit gentle assisted shoulder exercises within the limits of pain for gradually increasing periods as pain subsides.
- b- Mild analgesic drugs.
- c- Local injections with hydrocortisone and novocaine are given.
- d- Pain reduction modalities as heat therapy or even deep X-ray is helpful.

#### **2) When the pain lessens.**

- a- A slow progressive active exercise program can reduce the symptoms and is continued for weeks or months until full movement is regained.
- b- Home program exercise.

### **II Manipulation**

In persistent cases: If stiffness persists, manipulation of the glenohumeral joint under general anesthesia is performed.

(It is not preferred because of the trauma of the tissues).

### **Warning**

It is important to warn the patient at the beginning of treatment that recovery may take many months, but at the same time give assurance that

eventually recovery is complete. The patient should not stop moving. Tell him, if pain is persistent, limit the amount of moving you do, but don't stop moving.

## **Physical Therapy**

### **1) In the early acute stage**

#### **Goals**

- Decrease pain.
- Decrease inflammation.
- Decrease muscle guarding.

#### **Methods**

- Exercises: active, active assistive or passive exercises.
- Pendulum exercises can be very effective-assistive home exercises for muscle relaxation. They are safe and the patient has complete control over the movement.
- Gentle movements for shoulder girdle and cervical regions for muscle relaxation and decreasing muscle guarding.
- Corner stretches exercise.
- Isometric shoulder exercise.
- General body exercises may benefit the frozen shoulder patient.
- Patient re-education:
  - The patient should be careful to avoid vigorous home exercises to prevent flare-up of the symptoms.
  - The patient should understand the importance of proper posture to help reduce stress on the shoulder and entire involved upper quarter.
  - Improved head-neck, shoulder girdle, and trunk positions may:
    - Decrease the activity in the cervical and scapular muscles.
    - Help relieve of local symptoms
    - Allowing for more normal shoulder motion.
  - Avoid forward head posture with the upper limb internally rotated and adducted to avoid muscle tightness and weakness to avoid abnormal shoulder joint mechanics.
  - Postural re-education and rehabilitation may include thoracolumbar mobility treatment techniques to reduce stresses on posture.

#### **N.B.**

Pain relief modalities as TENS, Cryotherapy, Phonophoresis, Iontophoresis and Laser. When pain and muscle guarding decrease the dysfunction can begin to be treated.

## **2) In the late stage of frozen shoulder**

### **Goals**

- To normalize shoulder movement.
- To improve soft tissue mobility throughout shoulder region.
- To improve joint mobility at the glenohumeral, acromio-clavicular and sternoclavicular joint.
- To improve muscle strength throughout shoulder joint region.
- To improve co-ordination throughout shoulder joint region.

### **Modalities**

- Ultrasound to facilitate a stretch of tissues.
- Heat to promote relaxation.
- Exercises:
  - (1) Joint mobilization techniques
    - a) Movement grades III and IV for accessory and physiologic movements should be used to stretch the involved tissues.
    - b) High-velocity thrust techniques can also be a useful tool to restore glenohumeral joint motion.
  - 2) Muscle stretching and soft tissue mobilization techniques for the shortening of the soft tissue structures are essential for restoration of motion.
  - 3) Muscle strengthening and co-ordination exercises are necessary for normalizing shoulder motion.
  - 4) Proprioceptive neuromuscular facilitation (PNF) exercises are extremely useful for restoring co-ordination and motor control besides strengthening exercises.

### **N.B.**

Strengthening of the weak muscle with stretching the tight antagonistic muscle groups is important to avoid muscle imbalance.

# **Lumbar Spondylosis**

## **Definition**

It is a chronic progressive degeneration of the facet joint and/or the inter-vertebral disc.

## **Pathology**

The intervertebral discs become fibrosed and frequently associated with osteophytes and osteoarthritis of the facet joints. Neurological complications can also be seen with degenerative joint/disc disease due to the foraminal encroachment that sometimes occurs. Degenerative joint/disc disease is more common in the cervical spine than in the lumbar spine.

## **Degenerative disc disease is characterized by**

1. Dehydration of the nucleus pulposus.
2. Narrowing of the inter-vertebral space.
3. Weakening and degeneration of the annular rings.

The inter-vertebral disc and the hyaline cartilage surface of synovial joint don't have a blood supply. The movement of body fluid is necessary for these structures to receive their normal nutritional supply. Therefore, loss of mobility contributes to early development of joint/disc degeneration because of the increased wear and tear to which the disc and joints are subjected when hyper-mobility exists. Thus, both joint hypomobility and joint hypermobility can contribute to the development of degenerative joint/disc disease.

## **Clinical features**

### **Onset**

Usually the pain starts gradual and does not become a problem until a few months have passed when it becomes constant. Acute pain may be precipitated by unaccustomed activity.

### **1. Pain**

A common site for pain is across the sacrum between the sacroiliac joints. It may radiate down one or both buttocks and to the lateral aspects



of one or both hips. Central pain can occur at L4, 5 S1 level. This disorder is asymptomatic in many cases. Whoever, in advanced stage, pain is present with any movements.

### **Referred pain**

- 1- Pain may radiate into a leg because of nerve root irritation. It tends to be dermatomal. The patient will have tenderness at the segmental levels.
- 2- Groin – L1.
- 3- Anterior aspect thigh – L2.
- 4- Lower third anterior aspect thigh and knee – L3.
- 5- Medial aspect leg to the big toe – L4.
- 6- Lateral aspect leg to the middle three toes – L5.
- 7- Little toe, lateral border foot and posterior aspect whole leg -S1.
- 8- Heel, medial side posterior aspect whole leg – S2.

### **Nature of the pain**

Dull or severe ache superimposed from time to time by sharp stabbing pain.

## **2. Paraesthesia**

This can follow dermatomal distribution and may be pins and needles, a sensation of ‘creeping ants’ or feeling of numbness.

## **3. Muscle spasm**

There is usually increased tone in erector spinae and in one or both quadratus lumborum muscles. There is often unequal tone between the hip abductors and also between the adductors. Sometimes one hamstring muscle is tighter than the other.

## **4. Limitation of movement**

All active and passive lumbar spine movements tend to be limited. Hip movements are often limited asymmetrically. Limiting factors are generally soft-tissue tightness more than spasm or pain (except during an episode of acute pain).

## **5. Muscle weakness**

The abdominal muscles may be weak. The gluteal muscles are often weak on one side. The muscles of the leg with referred pain are usually weaker than the other. Pressure on a nerve root can result in weakness of the muscles supplied by that root (myotome).

## **X-ray findings**

There is usually narrowing of the disc spaces and some lipping of the vertebral bodies. There is often little correlation between X-ray findings and the disability of the patient.

## **Treatment**

### **Physical therapy**

#### **Goals**

1. Relief of pain.
2. Restoration of movement.
3. Strengthening of muscles.
4. Education of posture.
5. Analysis of precipitating factors to reduce recurrence.

## **Methods**

### **1. Heat**

- A heat pad can help to relieve the aching which comes from prolonged muscle spasm.
- The best position is lying with one pillow under the head and two or three under the knees.
- Sometimes it is helpful to warm tight muscles in a stretched position.

### **2. Ultrasound**

This is very useful for treating of erector spinae, quadratus lumborum.

### **3. Corsets**

- Generally corsets are not indicated in these patients because mobility and good postural muscle tone are important.
- Short-term elasticated strapping may be helpful during an episode of acute pain.

#### **4. Manipulative therapy**

**a. Mobilizations** is applied to stiff segments of the lumbar spine, sacroiliac and hip joints.

**b. Soft-tissue techniques** by passive stretching of tight structures is also essential. Kneading and friction massage are all important in restoring mobility to supraspinous ligaments, quadratus lumborum, erector spinae and glutei.

**5. Manual or mechanical traction** is applied under the same principles as for the cervical spine.

**6. Muscle strengthening:** the amount of lordosis will also help determine which exercises are appropriate with each patient. If the patient is hyperlordotic, flexion exercises are indicated; if hypolordotic, extension exercises are indicated.

#### **Advices**

- Sleeping on a firm mattress generally helps the patient whose problem is backache on waking, especially when the ache is aggravated by prolonged flexion.
- If the ache is aggravated by extension (where lordosis is the problem) a hard mattress can be quite wrong.
- If the patient sleeps in side-lying rather than supine the mattress should be soft enough to accommodate the body contour. Also the patient should try supporting the waist with a roll and the top arm and leg with pillows.
- Work out the precipitating factors, e.g. car seat, desk height, shape, size and weight of objects handled at work, sitting position (including side-sitting always one way).
- The patient should understand the importance of general fitness in the prevention of recurrence.

## **Spondylolysis**

### **Definition**

A condition in which there is a defect in the pars-interarticularis of a lumbar vertebra. The pars-interarticularis is the spur of bone joining the inferior articular process and lamina to the superior articular process and pedicle.

### **Etiology**

Spondylolysis is believed to be a sort of stress fractures (fatigue fracture) or congenital abnormality results in fibrous tissue replacing the narrow part of the pars interarticularis.

### **Clinical features**

- 1- Often there are none attributable to the defect directly. It is often symptomless.
- 2- The condition can be seen on radiographs and may be discovered by chance. Oblique view demonstrates the case.
- 3- Commonest site affected is L4/5 and L5/S1.
- 4- Sometimes it causes low back pain which is relived by rest.
- 5- Cases with symptoms are treated by a lumbo-sacral belt.

### **Prognosis**

- 1- The condition may not give rise to any symptoms.
- 2- The part of the vertebra above the defect may slip forwards and the condition is then known as spondylolithesis.

## **Spondylolisthesis**

### **Definition**

This means that the body of a vertebra slips on the one below. Generally the direction of the slip is forwards; occasionally there is a backward slip (retrolysthesis).

### **Etiology**

Common sites are L5/S1 and L4/L5. The stability of the L4/5/S1 part of the lumbar spine depends on the pedicle, pars interarticularis and inferior articular facet locking over the superior facet of the vertebra below. When the pars interarticularis 'gives', the vertebra slips forwards.

### **Incidence**

Age group is 40 or more; however females are much more commonly affected than males.

### **Causes and predisposing factors:**

- (1) Spondylolysis leads to separation of the pars interarticularis.
- (2) Degenerative changes leads to subluxation of the facet joints.
- (3) Congenital underdevelopment of the superior articular facets can enable L5 to slip forwards on the sacrum.
- (4) Fracture due to trauma.
- (5) Pathological weakening of bone (malignant or osteoporosis).

### **Clinical features**

#### **Symptoms**

1. The condition may be symptomless
2. Low backache is characteristic with muscle spasm a dominant feature.
3. Sometimes it feels as if the lumbar spine is locked in extension and the patient has a lordosis at L4/5/S1.
4. Pain is relieved on lying and aggravated by prolonged standing and activity. Sitting may at first relieve but later aggravates.
5. Referred root pain in the legs and sciatic radiation can occur.

#### **Signs**

1. Increased lumbar lordosis.

2. Forward flexion of the spine is limited.
3. Palpable step in the lower lumbar spine caused by relatively prominent spinous process of the displaced vertebra.
4. Lateral view reveals the degree of forward displacement.

## **Treatment**

### **I. Non-operative treatment: Cause 2 (Degeneration)**

1. Pain can be relieved by warmth and heating.
2. A lumbo-sacral support helps to relieve pain. A support or brace that provides abdominal compression will also help reduce vertical loading of the spine which may further reduce stress and aggravation due to physical activity.
3. Active exercises are essential when acute pain has subsided to strengthen abdominal and back extensor muscles.
4. Advice on posture, back care and lifting is essential.
5. Loss of weight is usually appropriate.
6. Mobilizations and soft-tissue techniques may be appropriate to restore movement to levels of the lumbar spine above the level of the lesion.

### **II. Operative**

Operative intervention is needed when symptoms are severe, the surgeon release the nerve roots (decompression) followed by fusion of the affected segments of the spinal column (spinal fusion).

## **Spinal Canal Stenosis**

### **Definition**

This refers to narrowing or abnormal configuration of the spinal canal (which becomes triangular instead of rounded or ovoid).

### **Etiology**

The condition may be developmental, with secondary degenerative changes to further narrow the spinal canal and precipitate symptoms. It may involve more than one segment, with L4-L5 and L3-L4 segments commonly involved.

### **Clinical Picture**

1. The patient is usually old male with a long history of back pain.
2. Pain in one or both legs with the typical sciatic distribution.
3. Patient gets pain and sense of weakness of the leg with prolonged standing, walking and hyperextension of lumbar spine.
4. Pain not stops when the patient stops walking.
5. Pain relieved by sitting, lying supine or alternates the hyperextension of the spine.
6. There is no constant positive spinal, stretch or neurological sign as in disc prolapse.

### **Treatment**

- Physical therapy modalities may provide temporary pain relief.
- Measures to increase mobility and flexibility (exercises and traction) sometimes help.
- A decompression Laminectomy is indicated in severe cases.

## **Lumbar disc prolapse**

### **Anatomical consideration**

The disc lies between two vertebral bodies (above and below). It consists of inner portion (nucleolus pulposus) and outer portion (annulus fibrosis), with upper and lower cartilaginous end plate.

#### **1. Nucleus pulposus**

Consists of colloidal jell, rich in water (88%), centrally located, except in lower lumbar (more posteriorly).

#### **2. Annulus fibrosis**

Consists of fibroid cartilage, with bundles of collagen, arranged crossed to withstand high bending and torsion loads.

#### **3. Cartilaginous end-plate** composed of hyaline cartilage.

- It separates vertebral bodies from annulus fibrosis.
- It contains pores for disc nutrition (as disc has no blood supply).

### **Function of the disc**

#### **1. Fluid balance:**

At night: Fluids are withdrawn in towards nucleus pulposus.

During the day: Fluids are drawn out, to complete a nutrient cycle.

#### **2. Intradiscal pressure:**

Intradiscal pressure of unloaded disc is 10 Newton per cm<sup>3</sup>(due to ligamentous force), it increases in standing, more increase in sitting, more in walking and further in running.

### **Causes of lumbar disc prolapse**

#### **1. Trauma:**

A single event trauma or repeated microtrauma, primarily from repetitive lumbar flexion and rotation movements, leads to degenerative changes that may result in herniated nucleus pulposus.

#### **2. Assuming body posture**

Such as stooping sitting as in drivers. This position drives the fluids from a high area of pressure (anteriorly) to the low area of pressure (posteriorly). This redistribution of fluids makes temporary changes in disc shape. If continued, the subject experiences difficulty in regaining upright posture.



### **3. Obesity.**

This causes repeated stress on posterior parts of the discs, predisposing it to rupture, specially lower ones (L4-5 & L5-S1).

### **4. Carrying a heavy weight**

It is a common direct cause, especially if it is accompanied by trunk flexion during raising the weight.

### **5. Pregnancy** may be a precipitating factor.

## **Incidence**

- **Age:** any age.
- **Sex:** 75-80% in males.
- **Sites:** About 90% of all lumbar disc herniation occur at the L4-5 & L5-S1 levels, so the L5, and S1 nerve roots are the most involved.

## **Manifestations (signs and symptoms)**

Clinical presentation of lumbar disc herniation varies because of the level, size, and position of herniation.

### **I Symptoms**

Not all lumbar disc herniation produce symptoms. In patients younger than 60 years 20% to 35% of lumbar disc herniations are symptomless.

#### ***A) Symptoms according to the direction of the lesion:***

- a. **Posterior lesion:** Low back pain.
- b. **Posterolateral lesion:** Low back pain and sciatica (L4-5 & L5-S1), and/or femoralgia (L2-3 and L3-4) according to the site of lesion. About 35% of patients with lumbar disc herniation develop true sciatica.
- c. **Lateral lesion:** Minimal or no low back pain, but sciatica or femoralgia are present. Also, may be motor weakness of the affected myotome(s), according to the level of lesion.

#### ***B) General Symptoms***

##### **1) Pain:** It may be:

1. Low back pain which is increased by spinal movement.
2. In the buttocks & thigh and is influenced by limb movement.
3. Radiated in the leg and foot & momentarily increased by coughing and sneezing.

- S1 radiates pain to the outer border of the foot.
- L5 radiates pain to the outer aspect of the leg and dorsum or inner aspect of the foot.

### **Character of Pain**

- **Pain** Increased by sitting, stooping, lifting and walking.
- **Pain** decreased by lying on the sound side, with slight hip and knee flexion.
- **Pain** may be accompanied by numbness.
- **Pain** can be quite severe, limiting all upright activities.

**2) Sensory loss:** due to neural compression

**3) Muscle weakness, and reduced reflexes:** due to neural compression and according to the level affected. It may be:

- **S1:** Gluteus maximus, calf, small foot muscles & decrease ankle jerk.
- **L5:** Gluteus medius, tibialis anterior (drop foot) and peronei (ankle reflex is normal).
- **L4:** Quadriceps and adductor with decrease knee jerk.

**4) The lumbar lordosis may be reduced**

**5) Compensatory lateral shift of the trunk**

## **II. Signs**

1. Scoliosis, usually lateral flexion occurs towards the affected side, less frequently to the opposite side.
2. Some rigidity of the lumbar spine with a tender point over the 5<sup>Th</sup> transverse process.
3. Tenderness on pressure on the buttocks of the involved limb.
4. Test for femoralgia (Ely's test): Patient prone, hip extension causes severe pain in the anterior aspect of the thigh.
5. Tests for sciatica:
  - Lasegue's sign: Passive straight leg rising with or without ankle dorsiflexion will cause severe sciatica, due to stretch of sciatic nerve.

- Nare's test: Forward bending from standing causes severe pain in the affected side, scoliosis towards the affected side and knee bending towards the affected side.
- Kering's sign: from Fowlers position, knee extension causes severe pain.

## **Management**

90% Of those patients with their first episode of sciatica improve with conservative care.

### **I. Drugs**

Analgesics, nonsteroidal anti-inflammatory, muscle relaxants and multivitamins. Antidepressants may be needed.

### **II. Surgery (10% of cases)**

- Laminectomy with or without discectomy (may be done through microsurgery).
- Percutaneous and endoscopic discectomy.

## **Indications of surgery**

### **1) Absolute indications**

Large central protrusion affecting multiple roots and may cause:

1. Progressive neurological deficit: Severe intolerable pain not responding to conservative treatment (medical & physical).
2. Bladder and bowel (Sphincteric) involvement (cauda equina syndrome).
3. Marked motor weakness.

### **2) Relative indications**

1. Chronic cases which symptoms are severe and cause disability with failure to respond to an active conservative treatment of at least 6 weeks.
2. Some relapsed cases and recurrent episodes of sciatica.
3. Significant neurological deficit with significant positive straight leg raise test.

### III. Injections

- A. Sacral epidural: Relief pain in 50% of cases.
- B. Lumbar extradural: Give excellent results.
- C. Chemonucleolysis: Give some complications as disc space infection, sensitivity reaction or recurrence.

### VI. Physical therapy

#### 1. Acute stage

- a. **Rest:** Rest for 3-4 weeks on hard mattress. Rest is complete but not absolute i.e. patient goes to W.C.
- b. **In patients without radiated pain:** In prone lying, this may close the tear before nucleus escape. It allows outer and vascular annulus to heal. This position is maintained by lumbosacral belt for 2 weeks.
- c. **In patients with radiated pain:** Side lying position with hips and knees flexed is the position of comfort for 2 weeks, then side lying for another 2 weeks with a pillow under lumbar region, affected side up (to open intervertebral foramen and allows disc to slide downward by gravity). This position is altered with fowlers position (supine, flexion hips and knees 90 degree and supported by pillows). The idea is that the rest helps regaining fluid balance of the disc between in & out pull of water to & from the disc respectively.
- d. **Plaster jacket:** For some persons e.g. business men who cannot be able to do rest. Plaster jacket fixes the lumbar spine in slight hyperextension and allows walking. It is used for 3 months.
- e. **Continuous lumbar traction:** For 2 - 3 weeks.
- f. **Light lumbar support (Corset):** For 3 months.
- g. **Starting program of weight reduction.**

#### 2. After acute stage

This is done in out patient clinic.

##### \* Source of heat (deep followed by superficial)

- Source of deep heat, mainly ultrasound is applied in a continuous form on the back  $\pm$  affected nerve root (obliquely on the gluteal region). Intensity is 1.5 watt/cm<sup>2</sup>, for 5 minutes. This is followed by superficial heat for 20 minutes.

- Moist heat is preferable than dry one (I.R.), as it takes the shape of the involved area and distribute heat equally over the affected area.

- Using superficial heat before deep heat causes vasodilatation of the superficial circulation and so decreases the effect of the followed deep heat.

**\* Pain killing electrical stimulation**

- Interferential current can be used in local Low back pain.

- TENS can be used in referred pain, applied on the course of the affected nerve (either femoral and/or sciatic) for 20 - 30 minutes.

**\* Lumbar traction**

Mechanical or electrical lumbar traction is applied for 15 minutes. Weight of the traction is more than 50% of body weight. Position of patient is crock lying, Fowlers or prone lying according to the patient comfort. Side lying position on the sound side can be applied, if there is a pure lateral prolapse. Both upper trunk and pelvis are fixed by pillows.

**\* Manual therapy techniques.**

**\* Exercises:**

**A. Graduated back exercises.** They start only after disappearance of radiated pain. They start by passive back extension (on arms from prone lying position), then raising head, head and arms from prone lying, then bridging exercises, then alternative hyperextension of both legs from prone lying, starting by the sound one.

**B. Lateral flexion trunk exercises,** from crock lying, if scoliosis is still present.

**C. Strengthening exercises** for the weak lower limb muscles if there is motor leg weakness.

**D. In mild cases, static and lower abdominal exercises** (knee to chest) can start after the end of back exercises, but with caution. Any exaggeration of symptoms or regaining of radiated pain means stoppage of exercises.

**E. Progressive activity resumption.**

**IV. Advices**

1. Wearing lumbar support in moderate and severe cases, especially during assuming positions rather than lying.

2. Hot foment on back & gluteal regions and on calf if it has a spasm. Frequency is at least 4 times per day, according to the severity of case. Time for each one is 20-30 minutes.
3. Avoid any source that increases intradiscal pressure i.e. abdominal exercises, cough, sneezing bearing down during constipation and back exercises if radiated pain is still present.
4. Use shoes without tie and avoid high heel in females.
5. Avoid lifting heavy objects. After recovery, ask the patient to follow proper way of weight-lifting (hips and knees flexion with trunk extension).
6. Ask the patient to continue in back exercises (after ending of sessions) for ever.
7. Avoid weight gain.

### **3) Physical therapy in Postoperative disc prolapse**

#### **Goals of postoperative rehabilitation**

Early patient's return to maximal functional status including:

1. Reduction of pain frequency and intensity.
2. Limitation of scar tissue formation
3. Maintenance of dural mobility.
4. Maximize strength and flexibility of lumbar paraspinal muscles.
5. Improve coordination
6. Prevent recurrence of injury.

#### **- Early physical therapy (from 1st day postoperatively)**

1. **TENS:** 20-30 minutes to decrease pain.
2. **Exercises:** breathing and circulatory ankle dorsiflexion exercises.
3. **Ambulation:** Patient lies prone firstly and then stands by supporting on his hands up on his legs. Returns to bed occur in the opposite sequences.

#### **- Late treatment:**

##### ***A. Before removal of sutures***

Add the following:

1. **Static back exercises** (from 6th day postoperatively).

**2. Knee flexion-extension exercises,** hip abduction-adduction exercises, if needed & static hip extension exercises.

***B. After removal of sutures***

Add the following:

- 1. Ultrasound** to break adhesions.
- 2. Manual deep friction massage** on suture lines for superficial adhesions.
- 3. Graduated back exercises,** dynamic hip extension exercises, hip flexion exercises (with knee flexion) exercises and static abdominal exercises.

***C. After 4-6 weeks***

Add Graduated dynamic abdominal exercises.

# Ankylosing Spondylitis

## Definition

Ankylosing spondylitis (AS) is a systemic rheumatic disorder characterized by inflammation of the axial skeleton and large peripheral joints. AS is one of the seronegative (-ve Rheumatoid factor) inflammatory arthropathy, progressing slowly to bony ankylosis. Ossification takes place in the spinal ligaments and finally there is complete rigidity of the whole spinal column.

## Aetiology

Unknown and genetic factors may play a role.

## Incidence

More in men than women in a ratio of 7.5: 1

## Onset

The disease starts in the second and third decades (Age: 15-30 years).

## Pathology

Pathological changes follow a constant sequence: inflammation of the sacroiliac joints → formation of granulation tissues → erosion of articular cartilage or bone replacement by fibrous tissue → ossification of the fibrous tissue → widening of joint spaces → bony ankylosis of the spine results. Articular cartilage, synovium and ligaments of vertebral joints may be affected. If many vertebrae are involved, the spine may become absolutely rigid. If costovertebral joints are involved, respiratory excursion is diminished.

## Stages of the disease

- 1) **Acute stage:** 1-2 years: Sacroiliac fusion, variable stiffness of the lumbar spine. No restriction of normal life.
- 2) **Remission and relapse stage:** Each relapse often is separated by several years, leaving a little or more stiffness in more joints.
- 3) **Late stage:** few remissions ending with fusion of the spine. The classical bamboo spine.



## **Clinical features**

- Low back pain, which is worse at night, in morning, or after inactivity and may be persistent.
- Limited spinal ROM and early morning stiffness.
- After inactivity stiffness in the spine and other affected joints.
- Limited expansion of the chest.
- Joint swelling (hips, shoulders, knees, and ankles).
- Chronic stooping (forward bending).
- Severe kyphosis may occur due to the effect of gravity.
- General feeling of malaise, loss of appetite, and weight.
- Fatigue, low grade fever, eye inflammation.

## **Radiological findings**

1. Early in the disease there is haziness of both sacro-iliac joints and the outline is no longer clearly identified. .
2. Later, the sacro-iliac joints are completely obliterated.
3. Vertical calcification of the longitudinal ligaments gives rise to typical “bamboo spine” appearance.
4. New bone formation at the junction of the femoral head.

## **Prognosis**

The natural history of the disease is one of slow progression of ankylosis, with long periods of remission interposed by exacerbation. Although there was functional impairment, most patients continued to be fully independent. Symptoms may be worsen, go into remission, or stop at any stage (self-limiting).

## **Treatment**

- 1) **Drugs:** salicyates and indomethacin may help to control pain.
- 2) **Rest:** Bed rest may be indicated during the acute painful stage of the disease. Use firm mattress or bed board with low or no pillow to avoid Kyphosis.
- 3) **Surgery:** In advanced cases
  - In cases that have severe Kyphosis spinal osteotomy in lumbar spine may be indicated.

- When both hips are ankylosed arthroplasty (total hip replacement) may be done.
- 4) **Radiation Therapy** to the spine is effective, but it has the risk of leukaemia.
- 5) **Physical and Occupational Therapy.**

## **Physical Therapy**

### **Aims**

1. To assess the patient.
2. To relieve pain.
3. To reduce stiffness, mobilize specific joints, and restore movement.
4. To maintain general mobility and posture.
5. To prevent deformity.
6. To maintain and improve physical endurance.
7. To advice or counsel.

### **Methods**

#### **1) Assessment**

**A) Posture:** Posture deviation occurs mainly in antero-posterior direction:

- Loss of lumbar curve.
- ↑ Kyphosis.
- Loss of cervical curve.
- Protrusion of jaw.

Methods used to assess posture are Spondylometer or Photography

#### **Spondylometer**

- It is used for measurement.
- It consists of an upright wooden post mounted at right angles to a wooden platform forming the base.
- The upright post is transacted at two inch intervals by short rods which are movable in a horizontal direction.
- The patient stands on the base with his back to the upright, the malleoli at a fixed distance and knees extended as possible. The vertebral spinous processes are centred over the tips of the rods.
- The rods are then adjusted so that they just touch the spinous processes.

- The patient steps off the platform and a spinal profile is apparent, and is recorded by plotting on graph paper.
- These measurements should be recorded at six-month intervals.

### **Photography**

- Photographic records of posture are reported at two-year intervals.
- Use lateral view and lateral view with trunk flexion and finger tip to toe position.

### **B) Spinal movement**

- *Spinal flexion & extension:* The patient stand in upright position with his back to the observer, the malleoli a fixed distance apart arms in anatomical position, and knees straight. Locate and palpate sacro-coccegeal position and mark on his skin. Mark C7. a tape measure is used to measure this distance between these two points. This measurement is repeated with the spine in full flexion and extension.

- *Lateral flexion:* It is measured by measuring the distance between the tip of the fingers and the floor with the patient standing erect and then bending sideward as far as possible avoiding forward or backward bending. Normal value is 12- 20 cm. Limitation of lateral flexion is one of the earliest diagnostic signs of the disease.

- *Cervical spine movements:* Measured by tape measurements.

- *Combined hip and spinal movement:* They are measured by asking the patient to flex his trunk as far as possible with arms and hands reaching towards the floor, and the knees maintained in extension. The distance between the tip of fingers and the floor is recorded.

- *Kyphosis:* It is assessed by “wall test”. The patient stands with his back to a wall. Normally heels, buttocks, scapulae and occiput can touch the wall simultaneously. In AS there is limitation of extension, measure the distance between the wall and tragus of the ear. Normal values are less than 14 cm.

### **C) Pulmonary function:**

Spirometer can be used to assess lung function, also chest expansion by using the tap. Patient must be reassessed regularly, every three months in the first two years, then at least every six months for one year.

## **2) Modalities**

1. Heat as hot packs for pain, muscle spasm and stiffness.
2. Ice is used for swelling management.
3. Hot baths and warm showers are used for relaxation.
4. Electrical stimulation as TENS for pain relief.

## **3) Therapeutic Exercises**

- Exercise is an integral part of any treatment program for AS.
- Patients must be encouraged to exercise their body and keep moving.
- Once joints fuse, physical treatment will not restore mobility.
- The exercise program is designed to improve or maintain mobility rather than strength, since muscle weakness is not a significant feature of the disease.

### **Exercises for ankylosing spondylitis patient should be:**

- Simple.
- Limited in number.
- Enough but not too much.
- Performed daily by the patient himself.
- Never to the point of pain or fatigue.
- Performed in midday or evening to be comfortable.

### **Types of exercises include:**

1. **Mobilization:** Maitland mobilization techniques and hyperextension mobilization exercises have particular value.
2. **Breathing exercises:** Deep breathing exercises to improve ventilation and to decrease chest deformity. Also, exercise connected with breathing which includes a combination of active movement of the trunk or extremities with deep breathing exercises.
4. **Stretching and flexibility exercises:** They are used for all tight muscles such as pectoralis and trunk muscles.
5. **Strengthening exercises:** For the muscle groups that oppose the direction of potential deformities as spinal extension exercises rather than flexors. However, using of light weights is encouraged, but uses of heavy weights are contraindicated.

#### **4. Advices**

- Always to sleep flat upon his/her back on a firm one mattress but not hard.
- Avoid using a pillow, if possible. Use of a small folded towel is suitable to prevent flexion deformity of the spine.
- Use back support if driving any distance in a car.
- Daily prone lying is the best exercise for maintaining good erect posture.
- Avoid excess calories and obesity to lessen body weight stress on joints.

# Physical Therapy of Osteoarthritis

## Definition

Osteoarthritis (OA) is a common chronic progressive degenerative articular disorder among adults of unknown cause characterized by gradual deterioration and loss of the cartilaginous weight-bearing surfaces of joints, presence of sclerotic changes in subchondral bone, and proliferation of new bone at the joint margins. The proliferation of new bone is manifest as osteophytes and spurs, which are evident on radiographs.

## Pathology of osteoarthritis

- Weight-bearing joints of the lower limbs and spine are most commonly involved. The articular surface becomes rough and the cartilage in the affected area degenerates, particularly at the points of greatest pressure. While at the margins of the joint osteophytes are formed.
- The lubrication mechanism of the joint is affected and it may become dry and creaky, even to the extent of the individuals being able to hear the joint crepitus. The muscles close to an affected joint may spasm as a protection mechanism to prevent painful movement, also muscles may be atrophied.

## Incidence

- Patients are usually over the age of 50.
- Both men and women are affected but the joint distribution pattern is different.

## Classification

**1- Primary osteoarthritis:** it develops spontaneously in middle age, and appears to be idiopathic. It can be localised or generalised

**2- Secondary osteoarthritis** has an underlying cause. It may develop in response to a number of different factors such as:

- 1- Trauma after severe injury, resulting in fractures of the joint surfaces, ligamentous injuries and meniscal damage.

- 2- Dislocation.
- 3- Infection.
- 4- Inflammatory arthritis
- 5- Loss of full range of motion, poor muscular power and strength
- 6- Loss of adequate joint alignment and deformity.
- 7- Obesity.
- 8- Hemophilia.
- 9- Hyperthyroidism.

### **Causes of osteoarthritis**

The cause is unknown but a number of predisposing factors may be considered:

- 1- Conditions already mentioned in relation to secondary arthritis.
- 2- Hereditary: There is a significantly higher incidence of the condition in families.
- 3- Poor posture and altered biomechanics the joint.
- 4- The ageing process in joint cartilage.
- 5- Defective lubricating mechanism and uneven nutrition of the articular cartilage, recurrent synovial effusion, and hemoarthrosis
- 6- Climate has not been shown to be related to the pathological changes but pain is greater in cold, damp climates.
- 7- Crystals (calcium pyrophosphate and hydroxyapatite) have been associated with synovitis in osteoarthritic joints.

### **Clinical Features**

#### **A. Physical signs**

1. Increased warmth, redness and fluid swelling in the joint during active inflammation.
2. Joint tenderness.
3. Joint enlargement.
4. Joint stiffness.
5. Joint crepitus on movement.
6. Reduction in the normal knee joint ROM
7. Muscle weakness and wasting.
8. Bony deformation as varus (bow leg) or valgus (knock- knee) may present in advanced cases of knee OA.

## **B. Symptoms**

1. Pain with or after movement: usually pain is exacerbated with activity and is worst at the end of the day and in bed at night.
2. Joint pain decreased or relieved with rest.
3. Swelling may be due to bony deformity such as osteophytes formation, or due to an effusion caused by synovial fluid accumulation after prolonged activity.
4. Feeling of stiffness in the affected joints. e.g. early morning stiffness of less than 30 minutes.
5. Reduced physical functioning.

## **Diagnostic investigations**

1. X-rays shows loss of joint space. There is subchondral sclerosis, altered shape of bone ends and osteophytes.
2. Laboratory tests are normal, and blood tests are normal unless the osteoarthritis is due to a biochemical condition such as gout, or a rheumatic disease such as rheumatoid arthritis.

## **Treatment of osteoarthritis**

Osteoarthritis cannot be cured but may be controlled with appropriate treatment. The goals of treatment are to relieve the symptoms and to manage the effects of progression of the pathologic process.

## **Benefits of treatment include the following**

1. Pain may be reduced or eliminated.
2. Range of movement can be extended.
3. Mobility can be improved.
4. Personal independence can be enhanced.
5. Further deterioration may be prevented.



**Treatment is usually either conservative or surgical in nature:**

**I. Conservative Treatment**

**A. Rest** may reduce compression and shearing on the joint and to allow inflammation to subside.

**B. Drug therapy** for relieving pain, including non-steroidal anti-inflammatory drugs (NSAIDs) or a local injection of steroids where necessary.

**C. Diet:** Most patients need advice in weight reduction

**D. Physical Therapy**

**Aims**

- 1- Relieve pain.
- 2- Strengthen muscles.
- 3- Mobilize joints.
- 4- Teach maintenance of joint range and muscle power.
- 5- Improve coordination.
- 6- Minimize deformity.
- 7- Train position sense to reduce postural stress.
- 8- Advise rest/activity relationship.
- 9- Help maintain and regain function.

**N.B.**

***Effective treatment of OA involves pain control and external force control.***

**1. Pain control**

- a. **Thermal agents:** paraffin bath, US, IR, heat pads, hot packs.
- b. **Hydrotherapy:** hot or cold packs because ice packs over the joint reduce pain and inflammation especially in acute cases
- c. **Electrical stimulation:** (TENS, interferential, or didynamic).

**2. External force control** is accomplished by

- a. **Reduction of the patient's weight** through diet and exercise regimes.

- b. **Using assistive devices** such as orthotics or ambulatory devices (a cane, crutches, or a walker) may be needed to reduce the weight-bearing load on the joint.
3. **The exercises recommended** for OA are
- a. **Free active exercises** and mobilization by restoring mobility and improving circulation can contribute to pain relief.
  - b. **A muscle - strengthening program:** The general principle is to work the muscles at a high repetition rate and against low resistance. The main muscles requiring strengthening are generally quadriceps, hip abductors and hip extensors. Knee extensor muscles should be developed and multiple angle isometric exercises are used to prevent muscle atrophy and to avoid excessive joint motion. Short-arc terminal extension exercises can be used to strengthen the quadriceps muscle.
  - c. **Strengthening exercises for all hip muscles** (SLR, abduction LR, adduction LR, extension LR).
  - d. Therapeutic strengthening exercises also include **isotonic, and isokinetic exercises**.
  - e. Resisted exercises are important for the muscles of any joint in which there are osteoarthritic changes.
  - f. **Appropriate proprioceptive neuromuscular facilitation** (PNF) techniques with slow reversals, repeated contractions, and stabilizations.
  - g. **Mobility of joints:** Mobilization as either accessory or physiological movements is invaluable at the earlier stages of the condition. Stretching the capsule and applying rhythmical movement facilitates synovial sweep across the cartilage and may help to diminish degeneration by improving nutrition. Compression and distraction are useful for the same reason. Mobilizations may be applied in the hydrotherapy pool with great success (pain relief and increased function) especially for the hip and lumbar spine. Grades I and II relieve pain and grade III reduces resistance fibrous thickening and tightening.

#### **4- Instructions and advice to patients:**

Instruction for the patient in joint use and maintenance of range of motion:

- Walking is good for lubrication and nutrition of the joint. Walk a little every day within limits of pain. Use walking aids to relieve pain and stress and to help balance.
- Rest 5-10 minutes every hour but avoid being in one position for longer than half an hour. If this is not possible, e.g. in a train or car, then practise isometric muscle contractions every so often.
- Exercise daily. If bed rest is necessary, as with 'flu' once the acute fever stage is passed and the joints have stopped aching try to move each joint in every direction every half hour or so. Also, practise isometric contractions.
- Weigh regularly, at least once a week. Try to keep weight under control.
- Avoid sitting with the knees crossed to prevent deformity.
- Do not sit or lie with a pillow under the knees.
- Avoid putting sudden strain on the joints, e.g. lifting heavy loads.
- Use a bag on wheels for shopping. Try to do a little every day rather than one big exhausting 'shop' once or twice a month. Carry two small bags, one in each hand.
- Do a little housework every day.
- In cold weather, wrap up well; cold predisposes to muscle spasm. Do not exercises from cold, use a rubber hot water-bottle or electric heat pad to warm the muscles prior to exercise.
- Use of a hot water-bottle is less dangerous than heat lamp and can mould to the part. A heat pad is more versatile.
- Although there is no cure, the effects of OA can be minimized so that functional capacity can be maintained. Patients sometimes need to be reassured that OA is not crippling as rheumatoid arthritis.

## **II. Surgical Treatment**

Main surgical techniques are:

1. Joint arthroplasty or making a new joint.
2. Osteotomy or the cutting of bone.
3. Arthrodesis or permanent fusion of the joint.

# **Rheumatoid Arthritis**

## **Definition**

Rheumatoid arthritis (RA) is an inflammatory polyarthritis with systemic manifestations. It is a condition characterized by exacerbation and remissions, some of which may be prolonged.

Rheumatoid arthritis is a systemic connective tissue disorder. It affects multiple joint systems throughout the body in a symmetric or bilateral presentation. The disease is characterized by inflammation in the synovial lining of joint complexes, which may be either acute or chronic, that result in articular cartilage and bone destruction. Such degenerative changes occur simultaneously in multiple joints, resulting in severe pain and limited mobility for activities of daily living.

## **Incidence**

Females are more affected in a ratio 3:1.

## **Aetiology**

1. Unknown.
2. Immunological factors.
3. Genetic factors.
4. Environmental triggers.
5. Infectious triggers.
6. Hormonal factors.
7. Stress.
8. Trauma.
9. Smoking
10. Diet

## **Pathology**

Pathological changes occur in synovium, arteries, and formation of subcutaneous nodules.

### **1- Synovium**

The main pathological feature is synovitis, i.e. inflammation of the synovial lining of joints, tendon sheaths and bursae. Excess fluid becomes trapped within joint capsules, causing swelling. If this continues the

synovium thickens, and excess synovium and fluid increase pressure within the joint, stretching and weakening the joint capsules and ligaments. Inflammation also directly infiltrates and erodes the capsule, ligaments, cartilage and subchondral bone, which leads to joint destruction and the development of deformities. Acute synovitis for a short period usually does not result in deformity. However, the longer a person has continuing synovitis, the more likely deformities are to develop.

## **2- Arteries**

- Small end arteries around the nail bed.
- Small arteries resulting in skin ulceration.
- Large arteries leading to gangrene.

## **3- Subcutaneous nodules**

These are characteristic firm nodules occurring in 25% of patients with RA. The common site is the ulnar side of forearm, olecranon and heel. They are not tender except when inflamed.

## **Clinical features**

Onset of the disease at any age and commonly begins in the fourth decades. However, the course of the disease is unpredictable.

## **Stages of the disease**

- Stage I: Synovium only is involved.
- Stage II: Early articular cartilage involvement.
- Stage III: Destruction of joint surface.

## **Symptoms**

- Pain & tenderness resulting from increased intra-articular pressure, leads to protective muscle spasm and restricts activity. It may occur with movement, but as the disease progresses it presents at rest.
- Joint swelling causes stretching and weakening of joint capsules and ligaments, resulting in joint instability.
- Warm feeling,
- Erythema,
- Decreased ROM
- Joint stiffness develops from the formation of joint adhesions. Morning stiffness is so characteristic.

- Muscle wasting results from reduced activity. The additional muscular work required of weaker muscles attempting to stabilize weakened joints results in muscles quickly fatiguing and aching.
- Deformity,
- Loss of function,
- Frustration, anxiety, depression
- Related diseases.

#### **(A) Articular sings**

##### **1- Synovial hypertrophy.**

**2- Subluxation and joint instability:** Joint subluxation results from erosion of cartilage, subchondral bone and ligaments, and secondary osteoarthritis can develop. These changes, combined with the mechanical stresses of weight- bearing and muscular forces arising from daily activities, produce deformity.

##### **3- Characteristic deformities:**

##### **- Deformities in the hand**

- Ulnar deviation at the MCPJ.
- Swan neck deformity of fingers.
- Boutonniere deformity. Over one-third of people with RA have hand deformities, with impaired hand function within two years of onset.

##### **- Deformities in the wrist**

- Palmar flexion and ulnar deviation.
- Dorsal subluxation ('dinner-fork' deformity)
- Wrist can no longer effectively achieve extension during power and other grips.
- Grip strength is on average only 20% that of healthy women.

##### **- Deformities of the elbow**

- Flexion

##### **- Deformities of the shoulder**

- Flexion & adduction

##### **- Deformities of cervical spine**

- Instability with subluxation of atlantoaxial joint

##### **- Deformities in the hips**

- Flexion deformity with external rotation.
- Aseptic necrosis of femoral head.

**- Deformities in the knee**

- Flexion deformity with varus or valgus component.

**- Deformities in the feet**

- Dropped metatarsal heads.
- Valgus deformity
- Pes planus

**(B) Extra- articular manifestations**

- 1- Fever, fatigue and weight loss.
- 2- Lymph node enlargement.
- 3- Subcutaneous nodules.
- 4- Involvement of tendons and bursae.
- 5- Arteries & vasculitis,
- 6- Spinal cord compression.
- 7- Peripheral neuropathy.
- 8- Lungs and pleura.
- 9- Skin.
- 10- Anaemia.
- 11- Myopathy.
- 12- Eye inflammations,
- 13- Heart & lung involvement,
- 14- Peri-articular osteoporosis.

**Radiological findings**

- Erosions.
- Soft tissue calcification.
- Changes in joint space.
- Osteoporosis.
- Subluxation of joints.

**Disability**

- 50% of patients have little or no residual deformity.
- 40% of patients have some disability.
- 10% of patients have severe disability.

**Prognosis**

Males have a better prognosis than females.

## **Impact of the disease**

1. RA can result in a wide range of impairments and dysfunction.
2. Frustration with the difficulty of performing everyday tasks, continual joint pain and fatigue may have a detrimental effect psychologically.

## **Management**

### **(1) Drugs**

- Analgesics, Non-steroidal anti-inflammatory (NSAIDs), and steroids
- Disease-modifying anti-rheumatic drugs: as gold salts, hydroxychloroquine, penicillamine and methotrexate as Apretid, Avara, Mabthera, are used early to
  - Prevent or reduce the erosive effects of RA
  - Pain relief,
  - Control inflammation,
  - Decrease disease process

### **(2) Rest**

- a) **General rest:** Adequate time between activities.
- b) **Local rest:** Complete immobilization is not preferred.
- c) **Bed rest:** in acute stages
- d) **Hospitalization:** in very severe disabling cases.

### **(3) Physical Therapy**

#### **Aims**

1. To evaluate the patient.
2. Educate the patient and his family
3. To relieve pain.
4. To maintain and restore ROM and mobility.
5. To maintain and restore muscle power.
6. To prevent deformity.
7. To correct deformity.
8. To maintain optimum function & performance in all ADL.
9. Increase joint stability.
10. Promote independence.



## Methods

### 1- Examination and assessment

Frequent re-assessment is necessary, because the disease is rarely static.

- **Range of Motion:** Goniometric measurement of passive ROM is indicated at all affected joints following a gross ROM assessment.
- **Strength:** Application of standard manual muscle tests to assess strength in RA may be inappropriate because of pain at various points in the range. A functional test of strength, therefore, is more indicative of rehabilitation needs and will identify the required functional outcomes of strengthening programs prior to initiating treatment.
- **Joint Stability:** The Ligamentous laxity of any affected joint should be fully investigated.
- **Functional Assessment:** Functional assessments may include ADL, work, and leisure activities.

### 2- Patient education

Explain carefully all about the disease, and the purpose of exercises and rest. The patient should learn to protect his joints, good posture and body mechanics.

### 3- Relief of pain

- **Heat:** can be used by various methods as hot packs, paraffin wax baths, and infrared. It aims to reduce pain and relax the muscles. Heat is recommended during disease remissions and chronic and not for acutely inflamed joints. It is used for RA to prepare joints for exercises.
- **Cryotherapy:** Cooling the muscle and skin to temperature low enough to affect conduction velocity of a nerve is most effective in reducing muscle spasm and in relieving pain. The most effective method is the application of ice towels or packs which are changed frequently.
- **Transcutaneous electrical nerve stimulation (TENS).**

### 4- Maintenance and restoration of joint range and patient mobility

### **a) Maintenance of ROM**

Patients are encouraged to put their joints through ROM daily:

- Active movement is preferred
- Active assisted movement may be necessary.
- Passive movement is not indicated.

### **b) Restoration of ROM**

- Repeated active movements into the limited range are encouraged and should be performed several times daily.
- Passive stretching for soft tissue limitations by using the force of gravity.
- Techniques of hold relax, contract relax and repeated contractions
- Hydrotherapy
- Maintain the gained ROM with voluntary control.
- Splints can be used to gain ROM.

### **c) Mobility of the patient and gait training**

- Reeducation of walking may be required. Walking aids may be chosen according to the state of upper limb joints. Sticks and elbow crutches with modifications can be used.
- Independent ambulation is recommended.

## **5- Maintenance and restoration of muscle power**

- Strengthening exercises should be performed daily because the disease has long course with primary and secondary effects on the muscles.
- The exercises should be designed according to patient's needs.
- Isometric and progressive resistive exercises are effective to improve muscle strength with careful supervision.
- Ensure that the resistance is not exceeding the range or stress the joints.
- The exercises must be within the limits of pain. If increased pain is felt and lasts more than two hours after exercise. Exercises should be decreased in amount and velocity.

## **6- Prevention of deformity**

**The methods used in preventing deformity are:**

- 1- Patient education.
- 2- Exercise.
- 3- Passive stretching.
- 4- Splinting

## **Splints**

- a) Rest splints
- b) Working splints

Splints may be used to:

- Relieve pain
- Reduce inflammation
- Protect weak joints from stress
- Preserve anatomic alignments
- Enhance function.

## **7- Correction of deformity**

- Conservative methods
- Surgical intervention

### **Conservative methods of correction**

- Serial splinting
- Intensive muscle strengthening program.
- Skin traction.

## **8- Maintenance of function & physical performance**

Aerobic-type exercise for at least 15 minutes performed at least three times per week is sufficient to improve the functional status of patients

## **9- Home program**

- Home program is essential in treating a RA patient.
- It is specific for each patient according to the physical examination.
- Teaching correct performance of an appropriate daily exercise program.

## **10- Community care**

Rheumatoid arthritis is a long term chronic disease affecting the patient's family and social life, and the provision of services is documented.

#### **(4) Surgical Treatment**

Surgery may be both preventative and corrective, and plays an increasing role in the management of chronic RA.

Indications for surgery:

- 1) Relief of incapacitating pain
- 2) Restoration of stability
- 3) Improvement of function
- 4) Prevention of harmful stresses on other joints.

#### **Common operations include:**

1. Synovectomy (e.g. wrist, MCPs) in 1st stage of RA.
2. Tenosynovectomy (e.g. finger flexors).
3. Joint replacement, most commonly of the hips, knee and MCPs, and also of the elbow and shoulder.
4. Arthrodesis or fusing the joint to eliminate pain and provide stability, especially in the ankles and spine where replacements have failed.
5. Reconstruction, repair and tenolysis on tendons.

## Total Hip Arthroplasty

One of the most widely performed surgical interventions for advanced arthritis of the hip joint is total hip arthroplasty. Osteoarthritis is the underlying pathology that accounts for most primary total hip procedures.

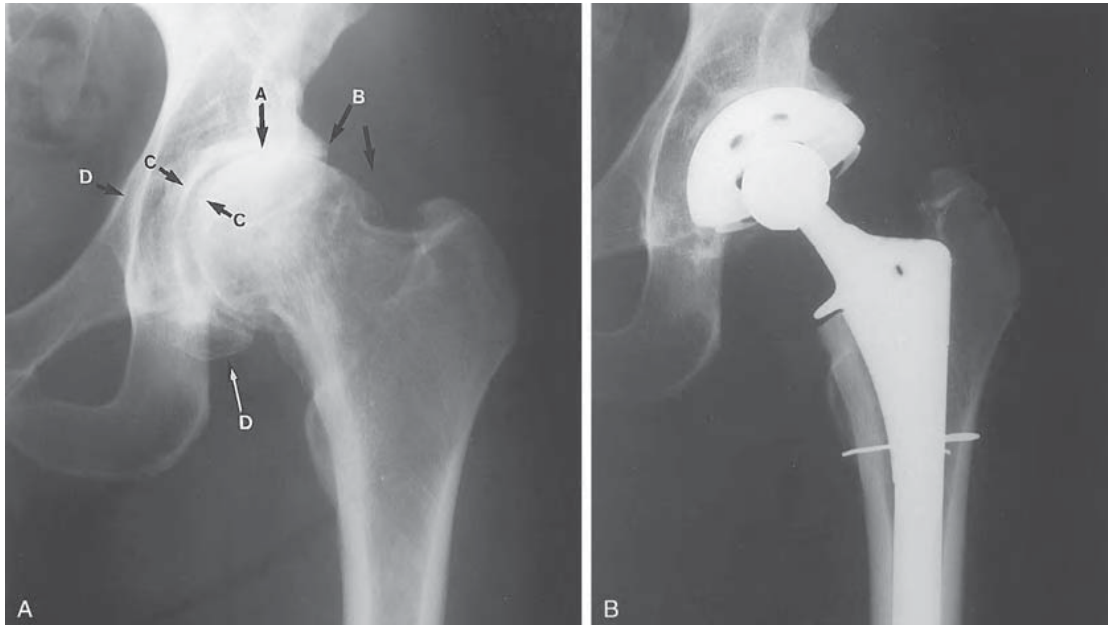


Figure: Total hip arthroplasty. (A) The preoperative severely degenerative hip joint. (B) Postoperative total hip arthroplasty.

### Indications for Surgery

Severe hip pain with motion and weight bearing and marked limitation of motion as the result of joint deterioration and loss of articular cartilage associated with osteoarthritis, rheumatoid or traumatic arthritis, ankylosing spondylitis, or osteonecrosis (avascular necrosis).

### Contraindications to Total Hip Arthroplasty

#### Absolute

- Active joint infection
- Systemic infection or sepsis
- Chronic osteomyelitis
- Significant loss of bone after resection of a malignant tumor or inadequate bone stock that prevents sufficient implant fixation
- Severe paralysis of the muscles surrounding the joint

## Relative

- Localized infection, such as bladder or skin
- Insufficient function of the gluteus medius muscle
- Progressive neurological disorder
- Highly compromised/insufficient femoral or acetabular bone stock associated with progressive bone disease
- Young patients who must or are most likely to participate in high-demand (high-load, high-impact) activities

## Procedures

## Background

### Prosthetic designs and materials

Total hip arthroplasty has been successfully performed since the early 1960s. A variety of implant designs, materials, and surgical approaches have been developed and modified over the years since the early replacements.

### Implantation of components and closure

After dislocation of the joint, an osteotomy is performed at the femoral neck, and the head is removed. The acetabulum is reamed and remodeled, and a high density polyethylene cup is inserted into the prepared acetabulum. The intramedullary canal of the femur may be broadened and a stemmed, metal prosthesis is inserted into the shaft of the femur. Trial components are inserted and checked radiographically to verify alignment of the components, and the hip is moved through a full ROM to assess its stability before the permanent implants are inserted. After the prosthetic hip is reduced, the capsule usually is repaired. The remaining layers of soft tissues that were incised or detached are securely repaired and appropriately balanced prior to closure.

## Complications

The incidence of intraoperative and postoperative complications after primary, traditional THA is relatively low. Intraoperative complications associated with THA include malpositioning of the prosthetic components, femoral fracture, and nerve injury. In addition to medical

complications, such as infection, deep vein thrombosis (DVT), or pneumonia that can occur after any surgery, postoperative complications that may occur during the early period of recovery (before 6 weeks or up to 2 to 3 months) include wound healing problems, dislocation of the prosthetic joint, disruption of a bone graft site before sufficient bone healing has occurred, and leg length discrepancy. Late complications include dislocation or mechanical loosening of the implant.

## Postoperative Management

### Immobilization

After THA there is no need for immobilization of the operated hip as postoperative rehabilitation emphasizes early movement. Depending on the type of surgical approach used and the stability of the prosthetic hip, the operated limb may need to remain in a position of slight abduction and neutral rotation when the patient is lying in bed in the supine position.

### Exercise and Functional Training Exercise: Maximum Protection Phase after Traditional THA

Common impairments exhibited by patients during the acute and subacute stages of soft tissue healing and the initial phase of postoperative rehabilitation after THA are pain secondary to the surgical procedure, decreased ROM, muscle guarding and weakness, impaired postural stability and balance, and diminished functional mobility (transfers and ambulation activities).

The emphasis of this phase rehabilitation after a standard surgical approach is on patient education to reduce the risk of early postoperative complications, in particular dislocation of the operated hip.

All patients routinely are asked to limit flexion of the hip to 90 degrees and rotation to 45 degrees for about 6 weeks regardless of the approach used. Selected exercises and functional training begin the day of or after surgery. The frequency of treatment by a therapist is often twice a day until the patient is discharged from the hospital, typically by 3 to 4 days postoperatively. Ideally, the prescribed exercises are performed hourly by the patient.

## Goals and interventions

The following goals and interventions apply to the initial postoperative days while the patient is hospitalized, continuing through the first few weeks after surgery when the patient is at home or in another health care facility.

### 1. Prevent vascular and pulmonary complications.

- Ankle pumping exercise to prevent venous stasis, thrombus formation, and the potential for pulmonary embolism.
- Deep breathing exercise and bronchial hygiene to prevent postoperative atelectasis or pneumonia continued until the patient is up and about on a regular basis.

### 2. Prevent postoperative dislocation or subluxation of the operated hip.

- Patient and caregiver education about motion restrictions, safe bed mobility, transfers, and precautions during other ADL.
- Monitor the patient for signs and symptoms of dislocation, such as shortening of the operated lower extremity not previously present.

### 3. Achieve independent functional mobility prior to discharge.

- Bed mobility and transfer training, integrating weight bearing and motion restrictions.
- Ambulation with an assistive device (usually a walker or two crutches) immediately after surgery, adhering to weight-bearing restrictions and gait-related ADL precautions.

### 4. Regain active mobility and control of the operated extremity

- While in bed, active-assistive exercises of the hip within protected ranges.
- Active knee flexion and extension exercises while seated in a chair, emphasizing terminal extension progressing to active hip and knee flexion (heel slides), gravity-eliminated hip abduction (if permissible) by sliding the leg on a low-friction surface, and active rotation between external rotation or internal rotation to neutral depending on the surgical approach. Do these exercises while lying supine in bed.



- Active hip exercises in the standing position with the knee flexed and extended with hands on a stable surface to maintain balance.
- Closed-chain hip flexion and extension, placing only the allowable amount of weight on the operated extremity.

#### 5. Prevent a flexion contracture of the operated hip.

- Avoid use of a pillow under the knee of the operated extremity.

#### NOTE:

- Arising from a low chair imposes particularly high loads across the hip joint; producing loads approximately eight times body weight.
- If the posterior capsule was incised during surgery, this places the involved hip at a high risk of posterior dislocation until soft tissues around the hip joint have healed sufficiently (at least 6 weeks) or until the surgeon indicates that unrestricted functional activities are permissible.
- Maintain a functional level of strength and muscular endurance in the upper extremities and unoperated lower extremity.
- Active-resistive exercises in functional movement patterns, targeting muscle groups used during transfers and ambulation with assistive devices. Prevent reflex inhibition and atrophy of musculature in the operated limb.

#### Precaution:

If a trochanteric osteotomy was performed, avoid even low-intensity isometric contractions of the hip abductors during the early postoperative phase unless initially approved by the surgeon and performed strictly at a minimum intensity.

#### Exercise: Moderate and Minimum Protection Phases

After traditional THA the intermediate and late phases of rehabilitation begin about 4 to 6 weeks postoperatively. The degree of protection of the operated hip required varies from patient to patient. Some degree of moderate protection may be necessary for 12 weeks postoperatively.

However, full healing of soft tissue and bone continues for up to a year after surgery.

Exercises and functional training focus on restoration of strength, postural stability and balance, muscular and cardiopulmonary endurance, and ROM to functional levels and gradual resumption and necessary modification of functional activities.

To prolong the life of the prosthesis, particularly in patients under 50 to 60 years of age, patients are routinely advised to refrain from high-impact sports and recreational activities. If a patient's employment involves heavy labor, vocational retraining or an adjustment in work-related activities is advised.

## Goals and interventions

### 1. Regain strength and muscular endurance.

- Open-chain exercises within the permissible ranges in the operated leg against light resistance. Emphasize increasing the number of repetitions rather than the resistance to improve muscular endurance.
- Bilateral closed-chain exercises such as mini-squats against light-grade elastic resistance or while holding light weights in both hands when unsupported standing is permitted.
- Unilateral closed-chain exercises such as forward and lateral step-ups (to a low step) and partial lunges with the involved foot forward when full weight bearing is permitted on the operated lower extremity.
- Resistive exercises to other involved areas in order to improve function.

### 2. Improve cardiopulmonary endurance

- Aerobic conditioning program, such as progressive stationary cycling, swimming, or water aerobics.

### 3. Reduce contractures while adhering to motion precautions

- Gravity-assisted supine stretch to neutral in the Thomas test position. Pull the uninvolved knee to the chest while relaxing the operated hip (At least 10 degrees of hip extension beyond neutral is needed for a normal gait pattern).

- Resting in a prone position for a prolonged passive stretch of the hip flexor muscles when rolling to prone-lying is permissible and is also tolerable.

- Integrate gained ROM into functional activities.

### Precaution:

Check with the surgeon before initiating a stretch of the hip flexors to neutral or into hyperextension if the patient has undergone an anterolateral approach.

### 4. Improve postural stability, balance, and gait.

- Emphasize use of a cane (in the hand contralateral to the operated hip) and progressive weight bearing on the operated limb.

- While using a cane, walk over uneven and soft surfaces to challenge the balance system.

- Integrate posture training during ambulation, emphasizing an erect trunk, vertical alignment, equal step lengths, and a neutral symmetrical position of the legs.

- Continue cane use until weight-bearing restrictions are discontinued or if the patient exhibits gait deviations, such as a positive Trendelenburg sign on the operated lower extremity, indicating gluteus medius weakness. Cane use is also recommended during extended periods of ambulation to decrease muscle fatigue.

### 5. Prepare for a full level of functional activities

- Integrate strength, endurance, and balance exercises into functional activities but continue to avoid applying high loads during exercise. When weight-bearing restrictions have been discontinued, strengthen hip and knee musculature with functional activities such as ascending and descending stairs step over step.

- Progressively increase the length of time and distance of a low-intensity walking program 2 to 4 days a week.

- When walking and carrying a heavy object in one hand, suggest that the patient hold it on the same side as the operated hip. Theoretically, this reduces the amount of stress imposed over time on the prosthetic hip replacement.
- Through patient education reinforce the importance of selecting activities that reduce or minimize the forces and demands placed on the prosthetic hip.

## Outcomes

THA and subsequent rehabilitation have resulted in a high degree of success related to pain reduction, improvement in physical function, and health-related quality of life. Reports say that THA results in good to excellent long-term results for 90% to 95% of patients.

## Early Postoperative Motion Precautions after Total Hip Arthroplasty

### Posterior/Posterolateral Approaches

#### ROM

- Avoid hip flexion 80° to 90°, adduction and internal rotation beyond neutral.

#### ADL

- Transfer to the sound side from bed to chair or chair to bed.
- Do not cross the legs.
- Keep the knees slightly lower than the hips when sitting.
- Avoid sitting in low, soft chairs.
- If the bed at home is low, raise it on blocks.
- Use a raised toilet seat.
- Avoid bending the trunk over the legs when rising from or sitting down in a chair or dressing or undressing.
- For bathing, take showers or use a shower chair in the bathtub.
- When ascending stairs, lead with the sound leg. When descending, lead with the operated leg.
- Pivot on the sound lower extremity.
- Avoid standing activities that involve rotating the body toward the operated extremity.
- Sleep in supine position with an abduction pillow; avoid sleeping or resting in a side-lying position.

## Anterior/Anterolateral and Direct Lateral Approaches With or Without Trochanteric Osteotomy

### ROM

- Avoid flexion 90°.
- Avoid hip extension, adduction, and external rotation past neutral.
- Avoid the combined motion of flexion, abduction, and external rotation.
- If the gluteus medius was incised and repaired or a trochanteric osteotomy was done, do not perform active, antigravity hip abduction for at least 6 to 8 weeks or until approved by the surgeon.

### ADL

- Do not cross the legs.
- During early ambulation, step to, rather than past, the operated hip to avoid hyperextension.
- Avoid activities that involve standing on the operated extremity and rotating away from the involved side.

## Hemiarthroplasty of the Hip

### Indications for Surgery

Acute, displaced intracapsular fractures of the proximal femur in an elderly patient with poor bone stock and an anticipated low-demand level of activity after surgery.

### Procedures

A posterolateral approach is most commonly used. After removing the head of the femur, the metal-stemmed prosthesis is inserted into the shaft of the proximal femur.

### Precaution:

Given the significant concerns for long term erosion of acetabular cartilage after hemiarthroplasty, it may be even more critical to avoid exercises that impose the greatest compressive or shearing forces across the hip joint and therefore pose the greatest potential for eroding the cartilaginous surface of the acetabulum. Exercises should be performed initially at a submaximal level and then progressed gradually.

## Total Knee Arthroplasty

Total knee arthroplasty (TKA), also called total knee replacement, is a widely performed procedure for advanced arthritis of the knee, primarily in older patients ( $\geq 70$  years of age) with osteoarthritis. The primary goals of TKA are to relieve pain and improve a patient's physical function and quality of life.

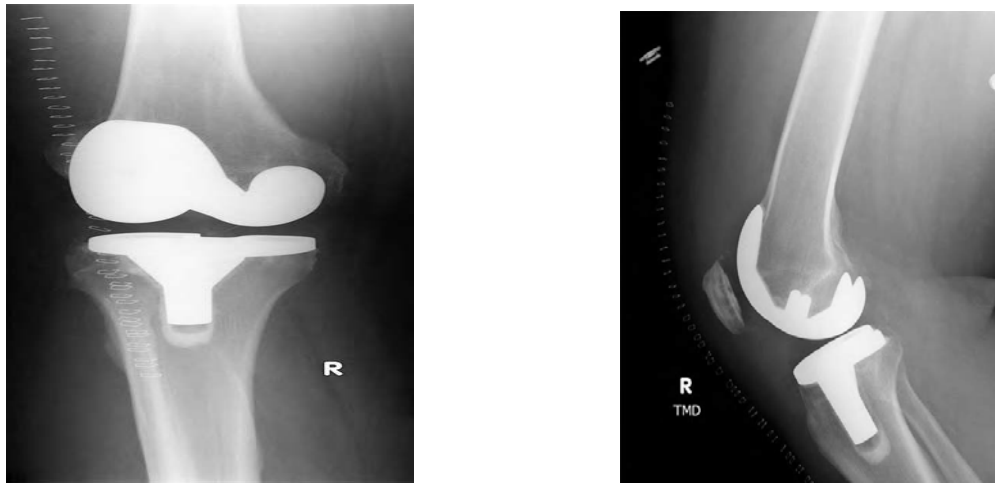


Figure: Total knee arthroplasty of the right knee with cemented fixation.

### Indications for Surgery

1. Severe joint pain with weight bearing or motion that compromises functional abilities
2. Extensive destruction of articular cartilage of the knee secondary to advanced arthritis
3. Marked deformity of the knee such as genu varum or valgum
4. Gross instability or limitation of motion
5. Failure of nonoperative management or a previous surgical procedure

### Procedure

#### Types of knee arthroplasty

Contemporary knee replacement procedures can be divided into several categories based on component design, surgical approach, and type of fixation. One category is based on the number of components implanted or articulating surfaces replaced. Most TKA procedures today involve a two component (bicompartamental) to replace the proximal tibia and distal femur. Occasionally, a tricompartmental design, which also resurfaces the

posterior aspect of the patella with a polyethylene component, is selected if the patellofemoral joint is symptomatic. For the younger patient (less than 55 years of age) with advanced disease of only the medial or lateral aspect of the knee joint, a unicompartmental design often is selected to replace just one tibial and one femoral condyle.

## Surgical approach

An open approach requiring a relatively long anterior incision traditionally has been employed to provide sufficient exposure of the knee joint during the procedure. A recent advance is the development of minimally invasive knee arthroplasty that involves a smaller incision and less soft tissue disruption to reduce postoperative pain and increase the rate of postoperative recovery.

## Fixation

The implants are held in place with acrylic cement, bone ingrowth (uncemented), or a combination of these two methods. Initially, almost all total knee replacements relied on cemented fixation.

## Operative Overview

One of several variations of standard or minimally invasive approaches along the anteromedial aspect of the knee can be used. A quadriceps-splitting is used to reach the capsule for an arthrotomy. The knee is flexed; and osteophytes, menisci, and the ACL are resected, the PCL is also excised. Small portions of the distal femur and proximal tibia are removed and prepared for the implants. If a patellar implant is indicated, the patellar surface also is prepared and the prosthesis inserted. Permanent components are inserted, and the capsule and other soft tissues are repaired. A sterile dressing is placed over the incision, and the area is covered from foot to thigh with a compression wrap.

## Complications

Overall, the incidence of complications after TKA is low. Intraoperative complications during knee arthroplasty, such as intercondylar fracture or damage to a peripheral nerve e.g. the peroneal nerve. Early and late postoperative complications include infection, joint instability,

polyethylene wear, and component loosening. As with arthroplasty of other joints, there is a risk of wound-healing problems and deep vein thrombosis (DVT) during the first few months after surgery are uncommon.

Other postoperative complications that can compromise a patient's functional recovery include limited knee flexion, joint instability leading to subluxation, and patellar instability or tracking problems leading to impaired function of the extensor mechanism (most often an extensor lag).

## Postoperative Management

### Immobilization and Early Motion

Typically, after primary TKA the knee is immobilized in a bulky compression dressing for a day, or sometimes continuous passive motion (CPM) is initiated in the recovery room or within a day after surgery. An extended period of immobilization may be required.

The position of immobilization after TKA usually is extension. Although atypical, an alternative approach is to immobilize the knee in a 90 flexion splint immediately after surgery and for brief intervals during the next day or two to achieve knee flexion as soon as possible while maintaining knee extension with exercises. During the initial postoperative period, it is advisable to have a patient wear a posterior extension splint during ambulation until quadriceps control is re-established.

The benefits of CPM, such as decreased need for postoperative pain medication, decreased incidence of deep vein thrombosis, and increased or more rapid recovery of ROM.

### Weight-Bearing Considerations

The extent to which weight bearing is allowable after primary TKA depends on the type of prosthesis implanted, the type of fixation used, the patient's age, size, and bone quality, and whether a knee immobilizer is worn during ambulation or transfers. With cemented fixation, weight bearing typically is permitted as tolerated immediately after surgery using crutches or a walker. During the first few days after surgery, use of a knee immobilizer may be required. The patient progresses to full weight bearing over 6 weeks.



Cane use is indicated as patient progresses from partial to full weight bearing. Ambulation without an assistive device, particularly during outdoor walking, is not advisable until the patient has attained full or nearly full active knee extension and adequate strength of the quadriceps and hip musculature to control the operated lower extremity.

## Exercise

### I. Exercise: Maximum Protection Phase

The first phase of rehabilitation extends for 4 weeks, is to control pain and swelling (with cold and compression), achieve independent ambulation and transfers while using a walker or crutches, prevent early postoperative medical complications, such as pneumonia and deep vein thrombosis, and minimize the adverse effects of postoperative immobilization. The goal is to attain 90° of knee flexion and full knee extension by the end of this first phase of rehabilitation. However, full knee extension may not be possible until joint swelling subsides. It is well established that pain and joint swelling limit the function of the quadriceps. Regaining quadriceps muscle strength, particularly in terminal extension, as early as possible after TKA is essential for functional control of the knee during ambulation and negotiating stairs. In addition to early postoperative exercise, neuromuscular electrical stimulation or biofeedback is recommended. The goals and exercise interventions for this phase of rehabilitation are the following.

#### - Prevent vascular and pulmonary complications.

- Ankle pumping exercises with the leg elevated immediately after surgery to prevent a DVT or pulmonary embolism
- Deep breathing exercises

#### - Prevent reflex inhibition or loss of strength of knee and hip musculature.

- Muscle-setting exercises of the quadriceps (preferably coupled with neuromuscular electrical stimulation), hamstrings, and hip extensors and adductors.
- Assisted progression to active SLRs in supine and prone positions the first day or two after surgery, postponing SLRs in side-lying positions for 2-4 weeks to avoid varus or valgus stresses to the operated knee.
- Active assisted ROM (A-AROM) progressing to assisted ROM (AROM) of the knee while seated and standing for gravity-resisted knee extension and flexion, respectively.

## II. Exercise: Moderate Protection Phase

The emphasis of the moderate protection phase of rehabilitation, which begins at about 4 weeks and extends to 8 to 12 weeks postoperatively, is to achieve approximately 110° knee flexion and active knee extension to 0° and gradually to regain lower extremity strength, muscular endurance, and balance. By 4 to 6 weeks postoperatively if nearly full knee extension has been achieved and the strength of the quadriceps is sufficient, most patients transition to using a cane during ambulation activities. This makes it possible to focus on improving the patient's gait pattern and the speed and duration of walking. The goals and exercise interventions for this phase of rehabilitation are the following.

### Increase strength and muscular endurance of knee and hip.

- Multiple-angle isometrics and low-intensity dynamic resistance exercises of the quadriceps and hamstrings against a light grade of elastic resistance or a cuff weight around the ankle. Perform in a variety of positions to strengthen knee and hip musculature.
- Resisted SLRs in various positions to increase the strength of hip musculature, with emphasis on the hip extensors and abductors.
- As weight bearing allows, continue or begin closed chain exercises as wall slides.
- Stationary cycling with the seat positioned as high as possible to emphasize knee extension.

### Continue to increase knee ROM.

- Low-intensity self-stretching to improve flexibility of the hip flexors, hamstrings and calf muscles.
- Stationary cycling with seat lowered to increase knee flexion.
- Inferior or superior patellar mobilization techniques to increase knee flexion or extension.

## III. Exercise: Minimum Protection and Return to Function Phases

From the 8th to 12th week and beyond after surgery, the emphasis of rehabilitation is on task-specific strengthening exercises, proprioceptive training, and cardiopulmonary conditioning so the patient develops the strength, balance, and endurance needed to return to a full level of functional activities. However, patients often are discharged from supervised therapy 2 to 3 months postoperatively after attaining

functional ROM of the knee and the ability to ambulate independently with an assistive device despite persistent strength deficits and functional limitations. Intensive exercise program during the late phases of rehabilitation are as ascending and descending stairs and returning to selected recreational activities.

## Recommendations for Participation in Physical Activities Following TKA

### Highly Recommended

- Stationary cycling
- Swimming, water aerobics
- Walking
- Golf

### Recommended If Experienced Before TKA

- Speed/power walking
- Low-impact aerobics
- Table tennis
- Rowing
- Bowling

### Not Recommended

- Jogging, running
- Basketball
- Volleyball
- Singles tennis
- Baseball
- High-impact aerobics
- Stair-climbing machine
- Handball
- Football, soccer

## Outcomes

- TKA can expect 10 to 20 years of satisfactory function before revision arthroplasty may need to be considered.
- Parameters typically measured to determine the success of knee replacement surgery are the level of pain, overall QOL, knee ROM, strength of the knee musculature, and a patient's ability to perform functional activities safely and with ease.

## Knee Synovectomy

Hypertrophic synovitis develops most frequently in patients with rheumatoid arthritis. Resection of proliferated synovium in patients without significant cartilage erosion alleviates pain and stiffness of the knee for a period of time. Although it is unclear if Synovectomy alters the course of the underlying disease, it delays the need for arthroplasty in the young patient.

### Indications for knee synovectomy

- Chronic, proliferative synovitis, joint pain, restricted joint mobility lasting 6 months or longer secondary to unremitting but early-stage rheumatoid arthritis that cannot be controlled by medical management.
- Synovial hypertrophy and joint pain secondary to recurrent hemoarthrosis as the result of hemophilia.
- Intact or minimally eroded articular surfaces.

### Procedures

Arthroscopic synovectomy involves removal of as much synovium as possible from all compartments of the knee; it is routinely preferred over an open approach. Also, Open synovectomy necessitates arthrotomy of the knee through a longitudinal medial and/or lateral parapatellar incision(s). However, an open approach may be selected by the surgeon if synovectomy is performed in conjunction with other open procedures.

### Postoperative Management

Postoperative management after arthroscopic synovectomy is progressed based on the patient's signs and symptoms rather than strict adherence to timelines. Exercises and weight-bearing activities are progressed relatively rapidly after arthroscopic synovectomy. A patient often achieves nearly full ROM of the operated knee and is able to ambulate without assistive devices as early as 10 to 14 days postoperatively depending on involvement of unoperated joints. Return to a full level of functional activity should occur gradually with some degree of protection continuing until joint swelling, limitation of active and passive knee ROM, and muscle weakness are resolved.

## Immobilization and Weight Bearing

The knee is immobilized for 24 to 48 hours in a compression dressing and a posterior splint that holds the knee in extension. During that time the leg is elevated to control postoperative edema. Ambulation with crutches begins the day of surgery, with weight bearing as tolerated. The patient should wear the posterior splint during ambulation until full, active knee extension has been achieved.

## Exercise

The choices and progression of exercises are based not only on the status of the operated knee but also on the extent of involvement of other joints of the upper or lower extremities affected by chronic arthritis.

### Exercise: Maximum Protection Phase

Immediately after surgery and for the next 2 to 3 weeks, early movement must be balanced with protection of the operated knee. Attention to wound care is particularly important because of the systemic nature of inflammatory arthritis. Regaining full, active knee extension is essential for ambulation without crutches or a cane. The goals and interventions implemented during the first phase of rehabilitation include the following.

#### Control pain and peripheral edema and decrease the risk of deep vein thrombosis.

- Elevation of the lower extremity and application of cold to the operated knee.
- Active ankle pumping exercises.

#### Regain or maintain neuromuscular control of hip and knee musculature on the operated side.

- Quadriceps and hamstring setting exercises performed frequently during the day
- Straight-leg raising exercises (SLRs) in the supine, prone, and side-lying positions.

## Regain ROM of the knee.

- Active-assistive knee flexion and extension exercises within the pain-free ROM.
- Gentle superior and inferior patellar mobilization techniques as swelling decreases.
- Gravity-assisted knee extension with a rolled towel under the ankle and the posterior aspect of the knee unsupported.
- Continuous passive motion (CPM), if requested by the surgeon.

## Exercise: Moderate, Minimum Protection and Return to Function Phases

As joint swelling and postoperative pain subside, emphasis is placed on re-establishing functional control of the operated knee necessary for independence during daily living activities.

## Outcomes

Synovectomy has been shown to be of benefit in alleviating chronic synovitis and joint pain and, in most cases, improving ROM and postponing deterioration of the involved joint. After recovery from surgery, joint pain and swelling are reduced in approximately 90% to 95% of patients.

## **Physical Therapy for Amputation**

**Definition:** Amputation means absence of the whole or part of a limb.

### **Causes of Amputation**

**I. congenital amputation:** Absence or abnormality of a limb evident at birth.

### **II. Acquired amputation:**

1) Traumatic amputation: loss of a limb or part of a limb due to trauma. It includes industrial injuries, severe burns or road traffic accidents. It occurs in younger adults.

2) Surgical amputation: surgical loss of the whole or part of a limb due to:

1. Peripheral vascular disease (PVD) which accounts for 80% of lower limb amputations, primarily affects people older than 60 years of age, as diabetic gangrene.

2. Trauma.

3. Malignancy and incurable bone disease as a life-saving measure for people with bone cancer as osteosarcoma or incurable bone disease, such as osteomyelitis.

4. Gross deformities as absence of the foot.

5. Flail limb

### **Goals for surgical amputation**

- To save the patient's life as in crush syndrome and tumors.
- To prevent spread of infection as in gas gangrene.
- To improve mobility and function as in gross deformity.

### **Levels of amputation of the lower limb**

1. Partial toe: transphalangeal amputation.

2. Toe disarticulation.

3. Chopart or transmetatarsals amputation.

4. Partial foot: Resection of the 3rd, 4th, 5th metatarsals and digits

5. Symes amputation: Ankle disarticulation with attachment of heel pad to distal end of tibia.

6. Below-knee amputation: (transtibial)

- a. Ideal standard level: Between 20 and 50% of the tibial length.
- b. Short transtibial amputation: less than 20% of the tibial length.
- 7. Knee disarticulation: Amputation through the knee joint; femur is intact. It is not preferred.
- 8. Above – knee amputation: (Transfemoral):
  - a. Ideal standard level: Between 35 and 60% of femoral length.
  - b. Short transfemoral amputation.
- 9. Hip disarticulation: Amputation through hip joint; pelvis remains intact. The entire femur is removed.
- 10. Hemipelvectomy: Hind quarter amputation: Resection of lower half of the pelvis with the entire lower limbs.
- 11. Hemicorpororectomy: The entire pelvis and limbs are removed, usually at L4-5 level.

### **Levels of Amputation of the Upper Limb**

- 1. Transphalangeal amputation
- 2. Partial hand amputation
- 3. Transmetacarpal amputation
- 4. Transcarpal amputation
- 5. Wrist disarticulation (Through-wrist)
- 6. Below – elbow amputation.
- 7. Elbow disarticulation.
- 8. Above - elbow amputation.
- 9. Shoulder disarticulation.
- 10. Forequarter amputation: this involves the removal of the whole arm, part of the scapula and most of the clavicle, usually because of a malignancy.

### **Importance of the residual limb**

- 1. Lever control
- 2. Complexity of fitting
- 3. Muscle mass retained
- 4. Force distribution
- 5. Proprioception
- 6. Weight loss
- 7. Degree of balance disturbances



8. Number of mechanical joints
9. Weight of prosthesis

## **Problems Related to Amputation**

### **1) Phantom Limb Sensation**

The amputee has the sensation that the missing limb is still present and 'normal'. The limb often seems to move, and may feel hot, cold or sweaty, especially in highly innervated areas such as the hands and feet. In most instances, this PLS is present immediately after surgery and often continues for weeks, months or even years.

### **2) Phantom Limb Pain**

Phantom limb pain (PLP) usually affects only a small number of amputees, severe pain that is variable in frequency, intensity and duration. Onset may not occur for weeks. The reason why PLP occurs is uncertain, but it seems to be linked with psychological and physiological mechanisms. It is exacerbated by emotional stress or cold weather.

### **3) Skin problems**

Sweating → maceration → infection.

Friction and bad pressure distribution.

### **4) Infection**

### **5) Edema**

### **6) Contractures:**

- Hip: flexion, abduction, and external rotation
- Knee: flexion
- Shoulder: flexion, abduction, and external rotation
- Elbow: flexion.

### **7) Acceptance or rejection of the prosthesis.**

### **8) Bone problems:** osteoporosis, spurs.

### **9) Scoliosis:** Patient with unequal leg length.

### **10) Neuroma:** at the end of cut nerve.

### **11) Psychological problems:** Depression.

## **Rehabilitation of the amputee**

### **Stages of Treatment**

- 1) Pre-operative stage.

- 2) Post operative:
- a. Pre-prosthetic stage.
  - b. Prosthetic training stage.
  - c. Functional adaptation stage.

### **Pre-operative stage**

This stage refers to people with chronic disease (such as PVD, malignancy and diabetes) for whom amputation has become the final option. Such people have a long medical and/ or surgical history.

### **Pre-prosthetic stage**

It is the time between surgery and fitting with a definitive prosthesis. The major goal of the pre-prosthetic period is to prepare the individual physically and psychologically for prosthetic rehabilitation.

### **Prosthetic stage**

Initial healing of the stump may be rapid in young, fit people, but can be delayed in people with vascular disease or diabetes. In all cases, the residual limb will initially be edematous and tender, and a permanent prosthesis cannot be fitted until tissues can tolerate some pressure, and the edema and post-operative swelling have dispersed. The patients usually use a temporary prosthesis in this stage.

**Temporary prosthesis:** It is immediately applied in few days.

### **Advantages of a temporary prosthesis**

1. It shrinks the residual limb more effectively than the elastic wrap.
2. It allows early bipedal ambulation.
3. Many elderly people who otherwise would not be ambulatory can walk safely with a temporary prosthesis and crutches during the pre-prosthetic period.
4. Certain individuals can return to work.
5. It reduces the need for a complex exercise program, because many people can return to full active daily life.

**Permanent prosthesis:** is fitted later. 6-8 weeks of stump wrapping usually will bring the stump to a satisfactory condition for fitting with prosthesis.

## **Physical therapy intervention**

### **Aims**

- 1- To control stump edema.
- 2- To provide stump conditioning.
- 3- To treat phantom pain.
- 4- To prevent post operative complications:
  - Infection, joint stiffness, contracture and deformities
- 5- To teach proper positioning for the stump.
- 6- To maintain and increase strength of the whole body:
  - Trunk muscles → for double amputees
  - Arms muscles → for crutch walking
  - Scapular muscles → for UL amputees
- 7- To increase strength of all muscles controlling the stump.
- 8- To maintain and increase general mobility of the joints.
- 9- To maintain and increase flexibility of the soft tissues and muscles.
- 10- To improve balance.
- 11- To educate, train the sound limb.
- 12- To improve general mobility of the patient and to train ambulation.  
To teach pt's transfers (bed mobility) as mobility from bed to wheelchair or to crutches.
- 13- To re-educate walking
- 14- Teach using of prosthesis.
- 15- To evaluate prosthesis and using it.
- 16- To restore functional independence.
  - ADL
  - Walking
  - Work
- 17- To provide psychological support.  
Depression / frustration  
Prescription of disability.
- 18- To instruct the patient about
  - Skin care

- Stump care
- Prosthetic care
- Donning / doffing

## **Methods of treatment**

### **I. Stump and Prosthetic care**

1. Stump care is of primary importance.
2. Prosthetic fitting is dependent on a good 'cone-shaped' stump, and initially this shaping is controlled using bandage, elasticized stump socks or figure-of-eight stump bandaging.
3. Gentle massage will help to desensitize the limb
4. Help the patient to adjust to his changed body image, as well as accepting his loss.
5. It is essential to establish good routines of hygiene and self-care as the stump must always be washed daily, and areas that cannot be seen should be inspected with a mirror for any signs of skin irritation or abrasion.

### **II. Positioning**

One of the major goals of the early postoperative program is to prevent secondary complications such as contractures of adjacent joints. The patient should understand the importance of proper positioning and regular exercises in preparing for eventual prosthetic fit and ambulation.

### **III. Exercises**

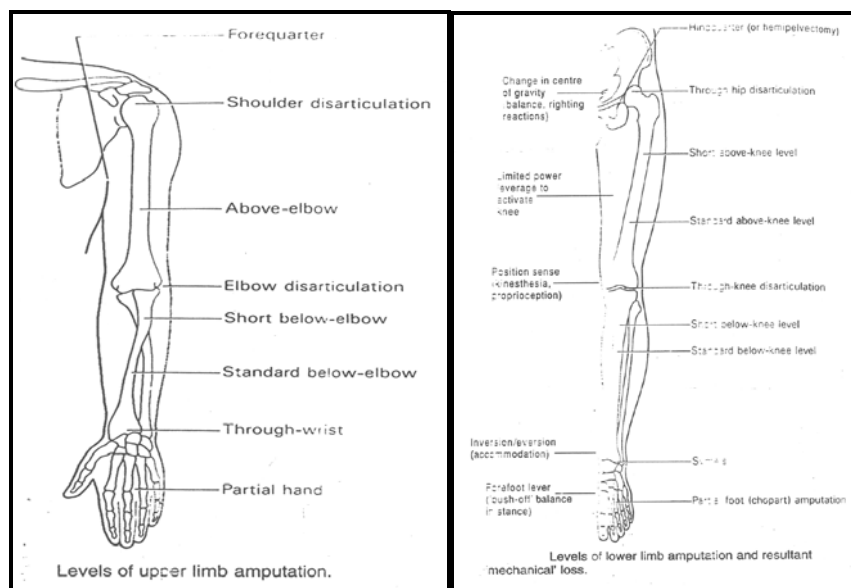
1. The exercise program is designed individually and includes strengthening and coordination activities. The hip extensors and abductors and knee extensors and flexors are particularly important for prosthetic ambulation. A 'general strengthening program that includes the trunk and all extremities is indicated particularly for the elderly person who may have been quite sedentary prior to surgery.
2. Active and resistive exercises for the uninvolved lower extremity, trunk, and upper extremities are initiated immediately after surgery.

3. Upper extremity strengthening exercise using weights, elastic bands, or manual resisted exercises are important. Shoulder depression and elbow extension are particularly necessary to provide the patient with a means of lifting the body from place to place.

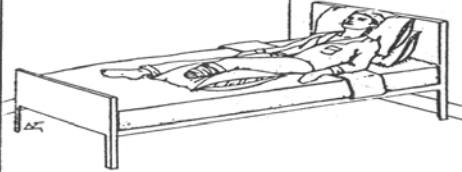
4. Walking is an excellent exercise and necessary for independence in daily life. Gait training can start early in the postoperative phase, and the individual with a unilateral lower extremity amputations can become quite independent using a swing- through gait on crutches.

## VI. Prosthetic training

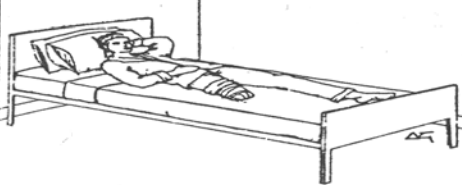
It starts with delivery of a permanent replacement limb. Prosthetic training usually begins with a temporary prosthesis, which allows gait training or bilateral upper limb activities to begin during the later stages of healing.



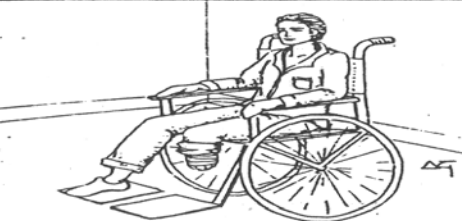## Do Not . . .



place a pillow under the knee while in bed

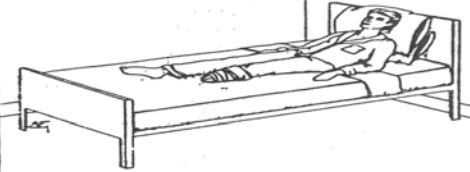


keep the above-knee residual limb abducted while in bed

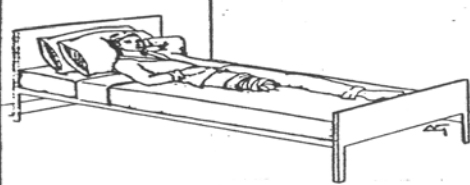

keep the knee in a flexed position when sitting

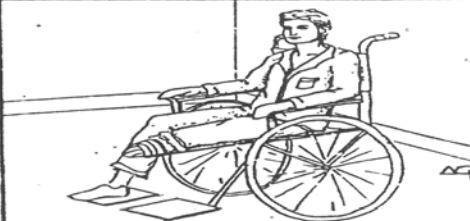## Do . . .



keep the knee positioned in extension while in bed

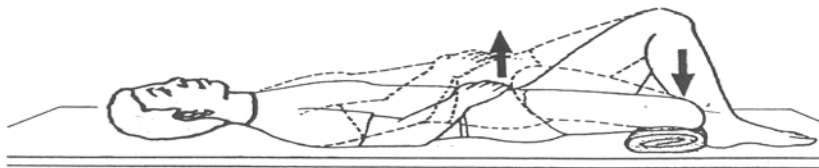


keep the above-knee residual limb adducted while in bed



keep the knee positioned in extension when sitting

Correct and incorrect positioning for below- and above-knee amputations.



Residual limb extension in supine position.

## General principles of fractures and joint injuries

**Fracture** is an interruption of bone continuity caused by trauma. A severe trauma is needed to fracture a healthy bone (**traumatic fracture**). A bone already weakened by disease may be fractured by mild trauma that is not sufficient to break a healthy bone (**pathological fracture**). A normal bone may crack from unusual repeated stresses, none of which is sufficient to cause a fracture (**stress or fatigue fracture**).

### Mechanism of injury:

1. **Direct trauma:** The bone breaks at the point of impact.
2. **Indirect:** The bone breaks at a distant from the point of impact.
3. **Muscle violence:** Powerful unexpected or uncoordinated muscle contraction may cause an avulsion fracture.

### Pathological anatomy

**Complete and incomplete fracture:** An incomplete fracture is a fissure, or green stick fracture.

1. **Fracture line:** A fracture in a shaft of long bone may be transverse , oblique,spiral,comminuted (more than one fragment)or at two levels (double level fracture).A fracture in cancellous bone may be impacted (one fragment is driven into the other).
2. **Closed (simple) and open (compound) fracture:** The skin is intact in a closed fracture .In an open fracture, there is a wound overlying the fracture site communicating the fracture haematoma to the exterior.
3. **Displacement:** The fracture fragments may be displaced causing a deformity .Displacement may be caused by the direction of trauma, effect of gravity and muscle pull. Displacement is described according to the position, which the distal fragment takes in relation to the proximal fragment and in the following terms: overlap, side displacement, angulation and rotation.

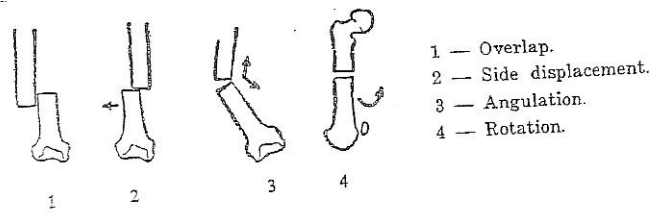


Fig. (1): Types of displacement.

4. **Stability:** A stable fracture is a fracture where further displacement after reduction is unlikely to occur; the reverse is true for unstable fracture. **Stability of a fracture depends on:**
- ♦ Line of fracture: Transverse fracture is more stable than oblique fracture.
  - ♦ Muscle pull: Unbalanced muscle pull tends to redisplace certain fractures.
  - ♦ Integrity of the supporting ligaments.

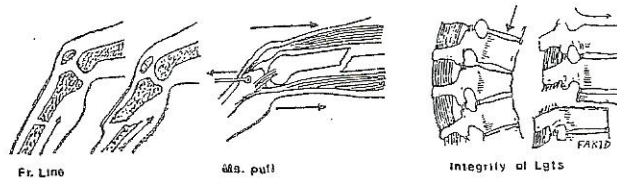


Fig. (2): Factors determining the stability of the fracture.

## Healing of fractures

### Factors essential of a fracture

1. Contact and apposition of the fragments.
2. Adequate blood supply of the fragments and intact tissues.
3. Fixation of the fractured parts.



## Clinical and radiological union

**Clinical union:** Clinically, there is no pain or tenderness over the fracture site, an x-ray may show the fracture line not completely obliterated but there is continuous bridge of the external callus, external fixation can be safely removed on clinical union of the fracture of upper limbs, but in lower limbs the fracture may be protected by allowing weight bearing partially and gradually, otherwise there is a risk of refracture.

**Radiological union:** The fracture is clinically united and an x-ray shows disappearance of the fracture line.

## Diagnosis of a fracture

**The diagnosis of a fracture is both clinical and radiological.**

### **Clinical diagnosis:**

The patient presents because of pain and instability to use the injured part (loss of function).

1. **History:** Description of the accident is known from the patient or the attendances.
2. **General examination:** For shock, head, visceral and other skeletal injuries.
3. **Local examination:** The signs of a fracture are:
  - ♦ **Tenderness:** Localized tenderness over a bone after an injury is sufficient for making provisional diagnosis a fracture until x-ray is taken.
  - ♦ **Swelling:** is evident in one hour, maximum in one day, and then gradually disappears after few days.
  - ♦ **Deformity:** Deformity is present when the fracture is displaced.
  - ♦ **Abnormal mobility:** Abnormal mobility can be elicited when the fracture is complete.
  - ♦ **Crepitus:** Crepitus is the friction sound between the fractured surfaces. The examiner need not elicit this sign because it is painful, can be harmful and is not essential for reaching the diagnosis of a fracture.

For the complete clinical diagnosis of a fracture, the motor and sensory innervation of the limb and the peripheral circulation should be examined to record and treat any injury of nerves or blood vessels.


## **Radiological examination**

1. The injured part must be examined in at least two views, anteroposterior and lateral views, more views are often needed in special cases.
2. The x-ray must include the joint adjacent to the fracture.

## **The treatment of the closed fractures**

### **First aid**

The injured part is splinted to protect it from further damage during transport .Usually an improvised splint is used at the location of the accident which may be a piece of wood tied to the side of the limb. In injuries of the upper limb, a triangular bandage is used as a sling. In the lower limb, the injured limb may be tied to the sound side.



**Fig. (3): First aid splintage of fracture.**

### **First treatment in hospital**

The patient is examined for shock, head and visceral injuries and for associated skeletal injuries or complications. Shock is treated. The management of internal hemorrhage and visceral injury takes priority over a limb fracture.

## **Definitive treatment**

The principles of treatment of a fracture are reduction, fixation and rehabilitation.

### **1. Reduction**

Most fractures are reduced by manipulation (closed reduction); certain fractures need operative reduction (open reduction).

**Aim:** The aim of reduction is to correct displacement.

**Time:** Early reduction of the fracture before the part gets swollen is preferable to delayed reduction after few days. Reduction is urgent when the fracture is complicated by vascular or nerve injury.

**Standard of reduction:** Accuracy of reduction is desirable in any fracture; particularly fractures involving articular surfaces. Angulation, rotation and overlap are not permissible especially in the lower limb. Partial side displacement is accepted in a transverse fracture of the shaft of a long bone.

### **2. Fixation**

Most fractures are splinted by plaster-of-Paris or by sustained traction on a splint, occasionally an external fixator is needed to secure fixation (external splintage). Certain fractures are internally fixed by a metallic implant (internal splintage).

**A. Plaster –of-Paris:** Is a fine powder of anhydrous calcium sulphate made from gypsum.

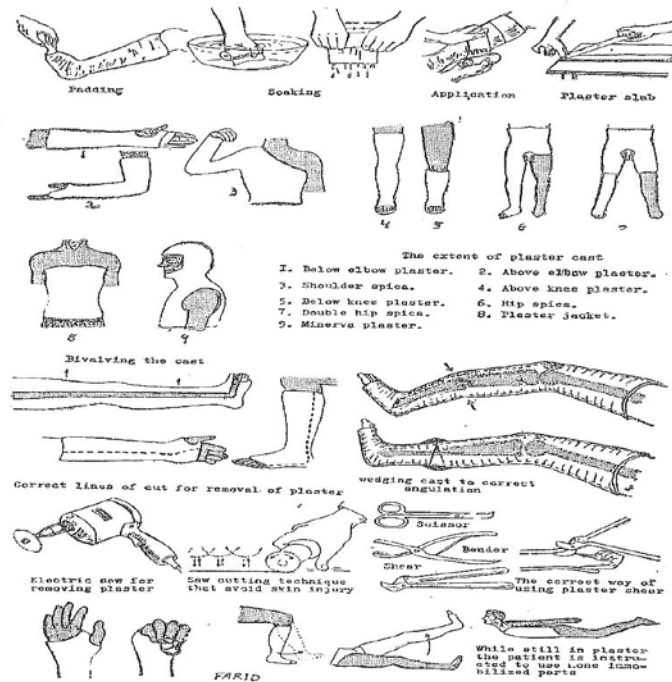
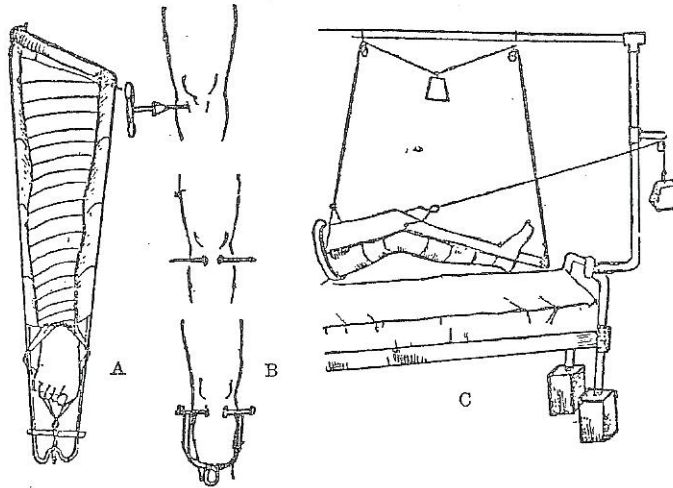


Fig. (4): Techniques of Plaster-of-Paris fixation.

**B. Sustained traction:** Traction overcomes the tendency of a fracture to displace because of muscle pull. It is a method of treatment of the shaft of the femur, cervical spine, some oblique fractures of the tibia and neck of the humerus.

## Methods of traction:

1. **Skin traction:** Skin traction is used in preference to skeletal traction in children when the pull need not be powerful or prolonged. Adhesive tapes are stuck on either side of the limb and held by gauze bandage. A cord is tied to the end of the tape for traction.
2. **Skeletal traction:** Skeletal traction is used in adults. A Steinmann's pin is introduced transversely into the upper end of the tibia behind the tibial tubercle for skeletal traction in hip or thigh injuries.



**Fig. (5): Traction for the lower limb:**

A: Skin traction.

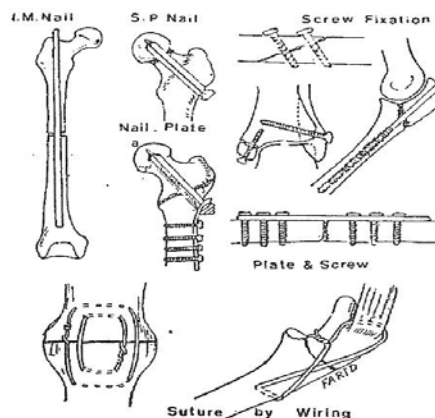
B: Inserting a Steinmann's pin behind the tibial tubercle for skeletal traction.

C: Balanced skeletal traction.

**C. Internal fixation:** A metallic implant is applied to serve as an internal splint for fractures.

#### **Methods of internal fixation:**

- Intramedullary nail.
- Nailing of fractures of neck of femur and nail-plate fixation of trochanteric fractures.
- Fixation by screws.
- Fixation by plate and screws.
- Fixation by wire sutures through bone.



**Fig. (6): Methods of internal fixation of fractures.**

### **3. Rehabilitation**

The aim is restoration of function of the injured part and the patient as a whole.

#### **Complications of fractures**

##### **General complications**

1. Hemorrhage and shock.
2. Fat embolism.
3. Venous thrombosis and pulmonary embolism.
4. Crush syndrome.
5. Complications caused by prolonged recumbancy.

##### **Local complications**

1. **Involving the fracture:** Malunion, delayed union and nonunion.
2. **Involving the bone around the fracture:** Avascular necrosis and sudecks atrophy.
3. **Involving the nearby joint:** Joint stiffness and osteoarthritis.
4. **Involving the soft tissues:**
5. **Nerve:** Nerve injury.
6. **Artery:** Injury to the artery.
7. **Muscles:** Tenosynovitis, tendon rupture.
8. **Viscera:** Injury of pelvis, spine or ribs.

## Injuries of the upper extremities

### 1. Fractures of the clavicle

**Patient:** Any age. In children, greenstick fracture can occur.

**Trauma:** Fall on the side of the shoulder or on the outstretched hand.

**Pathological anatomy:** The site of fracture is usually in the middle third at the junction of its two curves. The lateral fragment is displaced downwards and medially by gravity, the sternomastoid muscle pulls up the medial fragment, and there is overlap. Fracture of the lateral end of clavicle is rare and is usually undisclosed.




Fig. (7): Fracture of the clavicle.

#### Treatment

**Reduction:** The patient is seated on a stool; the surgeon stands behind the patient and braces the shoulder backwards.

**Fixation:** The axilla is padded with cotton and figure –of-eight bandages is applied for two weeks. The bandage needs tightening at least every second day to be effective.

**After care:** The patient is instructed to exercise the fingers and elbow from the first day and the shoulder after two weeks.

## 2. Dislocation of the shoulder

### A. Anterior dislocation

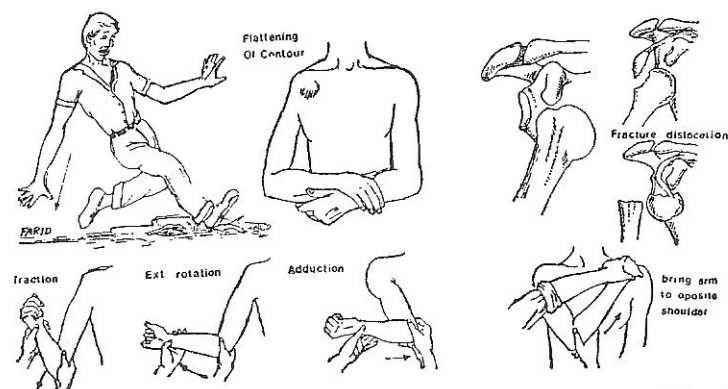
**Patient:** An adult.

**Trauma:** Fall on the outstretched hand with the arm abducted and often the limb behind the trunk.

**Clinically:**

1. There is severe pain and tenderness.
2. Flattening of the lateral contour of the shoulder and the arm is held with the elbow away from the trunk.
3. The humeral head can be felt behind the anterior axillary fold in the subcoracoid region.
4. Shoulder movements are painful and limited.
5. The patient is examined for circumflex nerve palsy, other nerve or vascular injuries.

**X-ray:** To detect associated fractures.



Anterior dislocation of the shoulder. The usual injury is a fall on the outstretched hand. There is flattening of the lateral contour of the shoulder and the head is felt displaced in the subcoracoid region. The dislocation may be associated with a fracture of the greater tuberosity or less commonly the neck of the humerus. Kocher's reduction consists of a sequence of traction, external rotation, adduction and then bringing the arm to the opposite shoulder.

Fig. (8): Anterior Shoulder dislocation.

**Treatment:**

**Reduction (Kochers methods)**

1. Downward traction on the arm to disengage the humeral head.
2. External rotation of the shoulder to overcome spasm of the subscapularis muscle.



3. The upper third of the humerus is levered outwards by adducting the shoulder, bringing the across the chest.
4. The shoulder then internally rotated carrying the hand to the opposite shoulder.

**Fixation:** The arm is bandaged to the side of the body for three weeks to allow healing of the torn capsule and to minimize the risk for recurrence

**After care:** The patient is advised to avoid putting the shoulder in the position of abduction –external rotation for three months.

## **B. Recurrent Dislocation of the shoulder**

**Patient:** Young adult, frequently in athletes and epileptics.

### **Pathological anatomy:**

Detachment of the labrum glenoid and the anterior capsule from the anterior margin of the glenoid.

### **Clinically:**

Re-dislocation occurs with increasing ease and frequency following usual every day activities as combing hair or reaching up to a high shelf. Reduction is equally easy and usually the bpatient can reduce the dislocation himself.

**Treatment:** Operation is indicated when disability is great.

## **D. Posterior dislocation of the shoulder**

**Trauma:** Less common than anterior dislocation, occurs in athletes and in epileptics.

### **Clinically:**

1. There is pain and inability to move the shoulder.
2. The shoulder is locked in internal rotation.
3. The front of the shoulder is flattened with prominence of the coracoind process.
4. The head of the humerus can be felt in the infraspinous region.

Posterior dislocation of the shoulder. Note flattening of the anterior contour of the shoulder and the posterior bulge due to the humeral head.

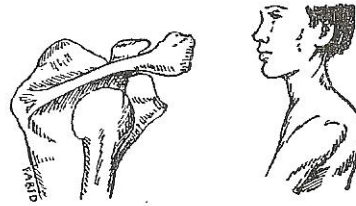


Fig. (9): Posterior shoulder dislocation.

### **Treatment:**

**Reduction:** Consists of traction, external rotation of the shoulder, while the humeral head is pushed anteriorly into the reduced position.

**Fixation:** The shoulder is fixed in the position of abduction and external rotation in a shoulder spica for one month.

## **3. Fractures of the humerus**

### **A. Fracture of the neck of the humerus**

**Patient:** Adult frequent in the aged.

**Trauma:** Fall on the shoulder, or on the out stretched hand.

**Clinically:** There is pain; swelling and ecchymosis of the shoulder region .Attempt movements are painful.

### **Treatment:**

**A. Fractures without separation (impacted fractures):** Don't need reduction. The arm is slug in a triangular bandage for two weeks after which, shoulder exercises are started.

**B. Fractures with separation (unimpacted fractures):** Need reduction either closed or open.

## B. Fracture of the shaft of the humerus

**Patient:** Any age.

**Trauma:** May be direct or indirect.

**Pathological anatomy:** The fracture may be in the proximal, middle or distal third of the shaft of the humerus. The fracture line may be transverse, oblique, comminuted or double level.

### Treatment:

**Fixation:** A padded U-shaped plaster slab is applied over the elbow and up the arm over the shoulder. The slab is fixed by a Plaster-of-Paris bandage. The arm is bandaged to the side of the body for the first month. Plaster is then changed into unpadded hanging cast with a collar and cuff sling until union of the fracture, which on average takes three months.

Certain fractures of the shaft of the humerus are better treated by internal fixation with plate and screws.

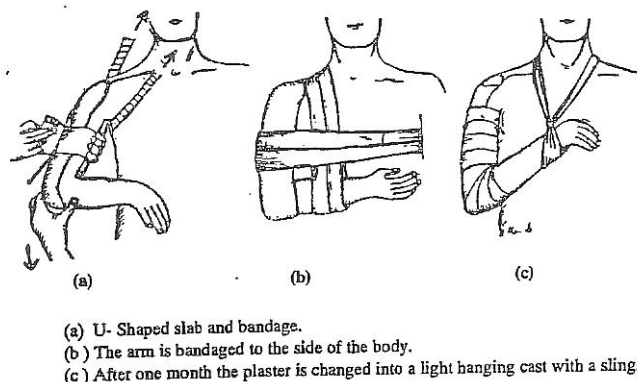


Fig. (10): Fixation of the shaft of the humerus.

**After care:** The wrist and fingers are exercised from the start. The patient is instructed to contract the elbow flexors and extensors actively (isometric contraction). Shoulder exercises can be started after removal of the plaster.

## C. Supracondylar fracture of the humerus

**Trauma:** Fall on outstretched hand.

### Clinically:

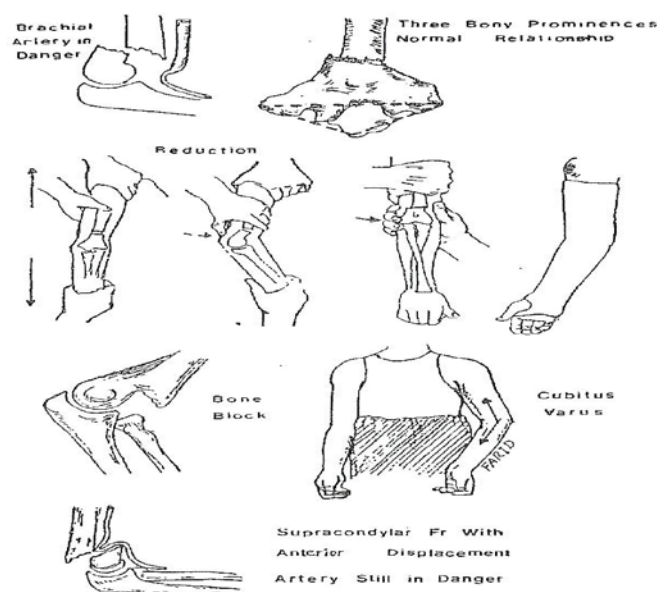
1. There is pain and swelling of the elbow region.
2. The relationship between the olecranon, medial and lateral epicondyles is normal.
3. Deformity caused by displacement of the condylar fragment may be evident.
4. The radial pulse should be felt and the hand should be examined for evidence of ischemia and nerve injury.

### Treatment:

**Reduction:** With the patient under general anesthesia, reduction is urgent to relieve the brachial vessels from any pressure.

**Fixation:** A posterior plaster slab extending from the axilla to the knuckles is applied and held in position by gauze bandage.

**After care:** The plaster is usually changed after 10 days when the edema subsides. The average period of fixation is 3 weeks. After removal of the plaster, the child is instructed to start active flexion of the elbow. No massage or passive movement is allowed.



**Fig. (11): Supracondylar fracture of the humerus.**

## 5. Dislocation of the elbow

### A. Posterior dislocation of the elbow

**Trauma:** Fall on the outstretched hand.

**Pathological anatomy:** The radius and ulna are displaced posterolaterally and the anterior capsule is usually torn.

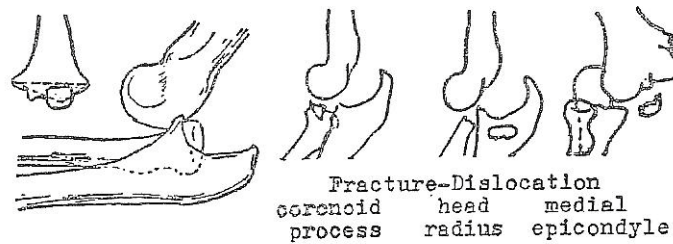


Fig. (12): Posterior dislocation of the elbow

#### Clinically:

1. Pain is severe.
2. The elbow is held in the position of 140 degrees of extension.
3. The deformity of the elbow is characteristics; the olecranon process is prominent and is raised above the line joining the humeral epicondyles. The lower end of the humerus is prominent in the Cubital fossa.
4. Movements are limited.

#### Treatment:

**Reduction:** The manipulation consists of traction along the forearm, then gently pushing the olecranon forwards.

**Fixation:** A plaster cast is applied with the elbow in 90 degrees flexion for three weeks.

### B. Anterior dislocation of the elbow

This is a rare injury due to fall on the point of the elbow. The olecranon process is fractured and the shaft of the ulna and the head of

the radius are displaced anteriorly .The dislocation is reduced and the olecranon is transfixed by a long screw nail.

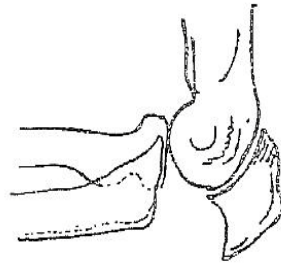


Fig. (13): Anterior dislocation of the elbow

## 5. Fracture of the upper end of the radius

**Trauma:** Fall on the outstretched hand.

**Clinically:** There is pain; swelling and tenderness over the radial head. Pronation & supination movements and elbow movements are painful and limited.

### **Treatment:**

- Fissure or mildly displaced fracture: Rest the arm for ten days in a sling or slab then start active exercises.
- Displaced sector or comminuted fracture: Excision of the head is indicated.

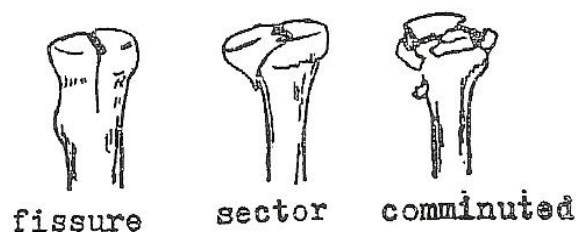


Fig. (14): Fracture of the upper end of the radius.

## 6. Fracture of the upper end of the ulna

### Fracture of the olecranon

Direct trauma as a result of fall on the point of the elbow may result in:

- a. Fissure fracture: This is treated by an elbow plaster cast for 3 months.
- b. Comminuted fracture of the tip of olecranon: This is treated by excision of the comminuted fragment and re-attachment of the triceps tendon. Muscle violence by triceps muscle may cause transverse fracture that needs internal fixation by wiring or screw.

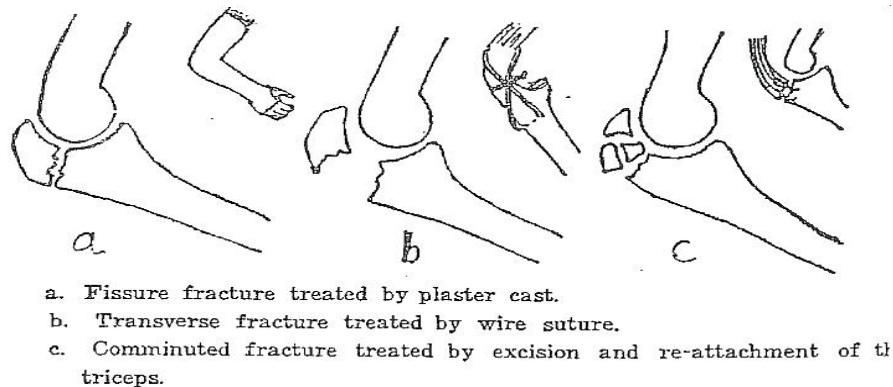


Fig. (15): Fracture of the upper end of the ulna.

## 7. Injuries of the forearm

### A. Fracture of the shaft of the radius and ulna

**Trauma:** Direct or indirect trauma.

**Pathological anatomy:** The fracture may involve the upper, middle or the lower thirds of the forearm.

**Treatment:**

**Reduction:** Perfect anatomical reduction is needed and can be achieved by closed reduction. If closed reduction fails or re-displacement occurs in plaster then operation is advisable.

**Fixation:** An above elbow plaster is applied with the elbow at right angle and the forearm in the desired position.

After care: The arm is elevated. The fracture needs from 2-4 months to be united.

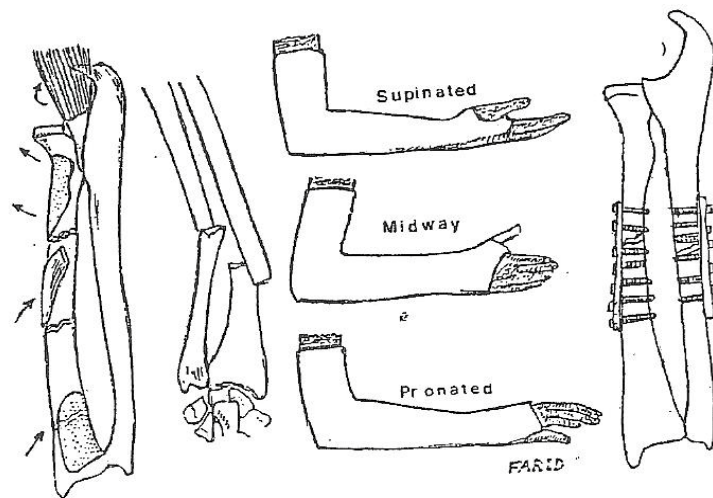


Fig. (16): Fracture of the forearm bones.

### B. Monteggia fracture-dislocation

In this injury, the ulna fractures near the junction of the upper and middle thirds and is angulated, the radius remains unbroken and therefore a dislocation of the superior radio-ulnar joint occurs. If the fracture and dislocation cannot be reduced by manipulation, open reduction is required.

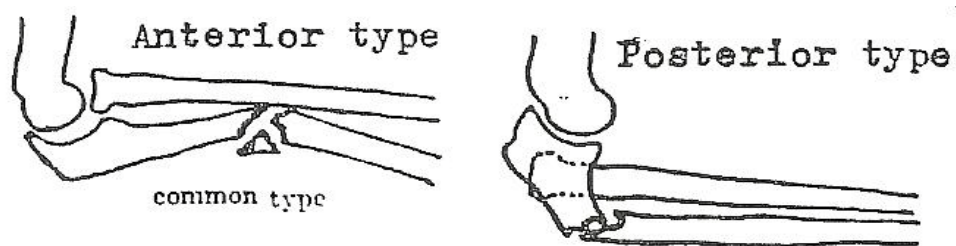
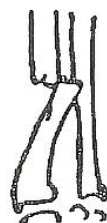

Fig. (17): Monteggia fracture-dislocation



## **B. Galeazzi fracture-dislocation**

The radius is fractured in its distal third and there is inferior radio-ulnar dislocation. The injury is best treated by open reduction and internal fixation, because of the tendency for re-dislocation.



**Fig. (18): Galeazzi fracture-dislocation**

## **8. Fractures of the distal end of the radius**

### **A. coll's fracture**

**Patient:** Adult and elderly.

**Trauma:** Fall on the outstretched hand.

**Pathological anatomy:** The fracture is within one inch of the lower end of the radius. The distal fragment is displaced upwards, backwards and radially, there may be subluxation of the inferior radio-ulnar joint. The ulnar styloid process may be fractured.

#### **Clinically:**

- ♦ Displacement causes the typical dinner-fork deformity.
- ♦ Pain in the distal part of the radius.
- ♦ The radial styloid process becomes elevated to the level of the ulnar styloid.

**Fixation:** A below elbow plaster cast is applied while the forearm is held pronated and ulnarly deviated.

**After care:** The patient is instructed to exercise the fingers and shoulder from the first day. The plaster cast may need to be changed

after two weeks when it becomes loose. Plaster fixation is maintained for five weeks.

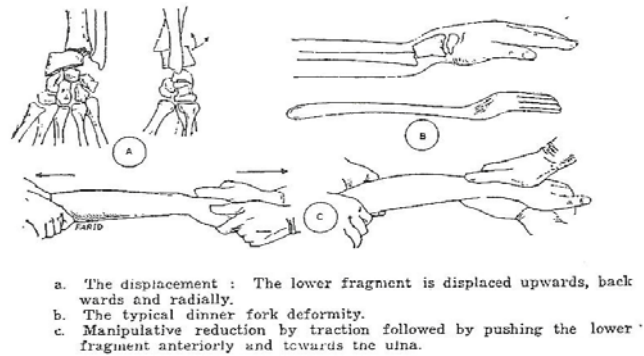


Fig. (19): Collis fracture

## B. Reversed coll's or smith fracture

This injury results from a fall on the dorsum of the hand .The distal fragment is displaced forwards. Reduction is achieved by manipulation and is maintained by an above elbow plaster cast for 5 weeks.

## 9. Fracture of the carpal scaphoid

**Trauma:** Fall on the outstretched hand.

**Clinically:**

1. There is pain and swelling of the radial side of the wrist.
2. Tenderness in the anatomical snuff box.
3. Wrist movements are slightly painful and limited.

**Treatment:**

The wrist is fixed in a below elbow plaster cast including the proximal phalanx of the thumb(thumb spica plaster)until there is radiological evidence of union of the fracture, even if this takes many months.

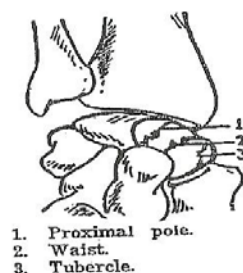


Fig. (20): Fracture of the carpal scaphoid

# Injuries of the lower extremity

## 1. Dislocation of the hip

### A. Posterior dislocation of the hip

**Patient:** Adult and may occur in children.

**Trauma:** A dash-board motor car accident, a fall from a height or a fall of a roof or heavy weight on a stooping person.

**Pathological anatomy:** When the hip is in the position of flexion and adduction, the femoral head is mostly over the posterior capsule. Any thrust along the shaft of the femur causes tearing of the capsule and posterior dislocation of the hip.

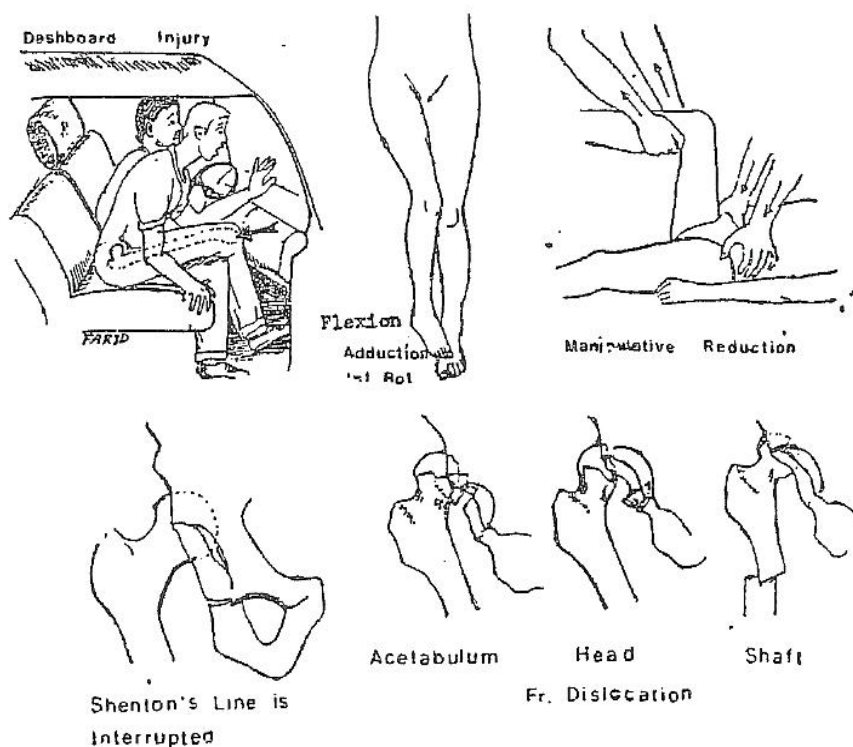


Fig. (21): Posterior dislocation of the hip

**Clinically:**

1. The history of the accident is taken, pain is severe.
2. The hip is in the position of flexion, adduction and internal rotation deformity.
3. The greater trochanter is raised and the femoral head is palpable in the gluteal region.
4. Movements of the hip are painful and limited.
5. There is shortening of the affected limb.

**X-ray:** The femoral head is outside the acetabulum, being displaced upwards and posteriorly.

**Treatment:**

**Reduction:** Under general anesthesia with the patient lying on blankets on the floor and an assistant is steadying the pelvis. The hip and knee are flexed to 90 degrees, rotating the limb to neutral and then lifting the femoral head into the acetabulum by vertical traction. The hip is then extended.

**Fixation:** A hip spica is applied for 6 weeks.

**After care:** After removal of plaster, the patient is allowed ambulation using crutches. Weight bearing is postponed for three months when x-ray shows normal density of the femoral head (no vascular necrosis).

## **B. Anterior dislocation of the hip**

Anterior dislocation of the hip is less common than posterior dislocation of the hip.

**Patient:** Usually an adult.

**Trauma:** A thrust on the femur with the hip abducted as can be caused by a fall of a heavy weight on the upper lateral side of the thigh.

**Pathological anatomy:** The femoral head is displaced anteriorly towards the obturator foramen or the pubic bone.

**Clinically:** Pain is severe; the hip deformity is flexion, abduction and external rotation. The femoral head is palpable in the groin. The limb is longer than the normal side.

**Treatment:**

**Reduction:** Under general anesthesia, the hip and knee of the affected side are flexed to 90 degrees. While an assistant is steadying the pelvis, the limb is turned into neutral rotation. Vertical traction on the thigh often causes reduction. The hip is then extended.

**Fixation:** A plaster hip spica is applied for 6 weeks.

**After care:** The same as with posterior dislocation.

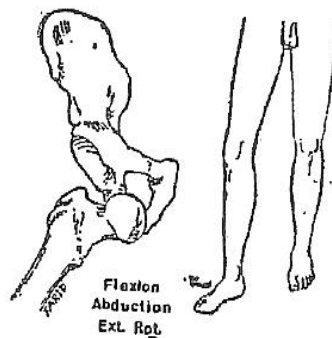


Fig. (22): Anterior dislocation of the hip

### C. Central dislocation of the hip

**Patient:** Adult.

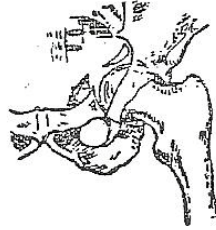
**Trauma:** The most common cause is a motor car accident or a fall from a height if the patient lands on his side.

**Pathological anatomy:** The floor of the acetabulum is broken. The separated segment of the acetabulum is pushed inwards with the femoral head.

**Clinically:** Pain is severe. All hip movements are painful and limited. The greater trochanter is less prominent than on the normal side.

**Treatment:** Skeletal traction for 6 weeks may succeed to improve the displacement. By physiotherapy, the patient may regain a useful range

of hip flexion. Surgery is said to improve the results but needs experience. Osteoarthritis occurs later on in most cases.



**Fig. (23): Central dislocation of the hip**

## **2. Fracture of the neck of femur**

**Patient:** The fracture occurs most commonly in the elderly, especially women, because of senile osteoporosis.

**Trauma:** This may be twisting injury as when the foot catches the edge of a carpet.

### **Clinically:**

*It should be the rule that any elderly patient who complains of pain in the hip region after an injury, even trivial, should be assumed to have sustained a fracture of the neck of femur until this is excluded by x-ray.*

### **The classical signs are:**

1. The hip is externally rotated.
2. The greater trochanter is raised.
3. The patient usually cannot raise the lower limb while the knee is straight.
4. Movements of the hip are limited.
5. Shortening of the limb is present.

**Treatment:**

Manipulative reduction and internal fixation, the operation is done as soon as the general condition of the patient allows.

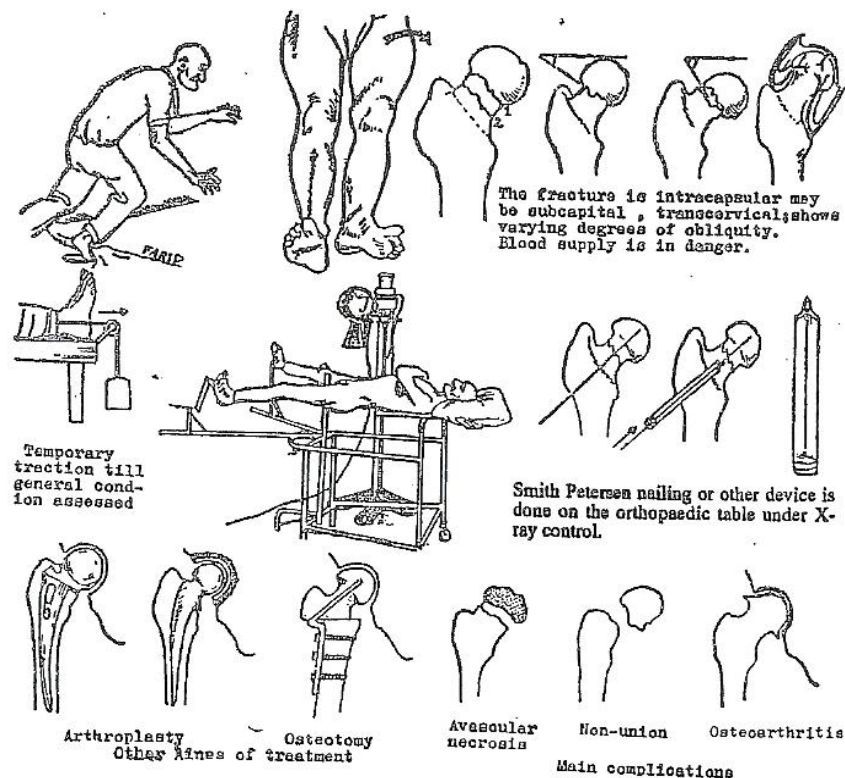


Fig. (24): Fracture of the neck of femur

### 3. Trochanteric fracture

**Patient:** Old, on the whole older than the patient with fractured neck of femur.

**Trauma:** Direct trauma as a fall on the side or indirect a stumble.

**Clinically:** The picture is similar to fractured neck of femur. In addition, external rotation deformity is marked, and ecchymosis of the Trochanteric region may be present.

**Treatment:** Because of patient age, it is preferable whenever possible to fix the fracture internally by nail plate. Patients unfit for internal fixation are treated by traction on a Böhler's splint.

## 4. Fracture of the shaft of the femur

**Patient:** Any age.

**Trauma:** May be direct or indirect. Motor car accident, a fall from a height is the commonest causes.

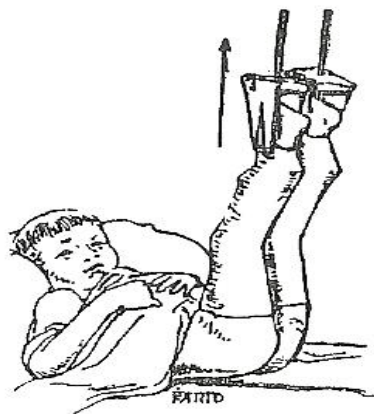**Pathological anatomy:** The shaft of the femur may be fractured in its proximal, middle or distal thirds. The fracture may be transverse, comminuted, and oblique or may be double levels. The powerful thigh muscles can cause gross displacement in the form of angulation and over-riding

**Clinically:** Shock may be severe. The classical signs of a fracture are present .Search is made for other injuries of the hip or knee of the same side and for other injuries in the body.

**Treatment:**

### 1. Treatment of fractured shaft of the femur in infant:

Both lower limbs are suspended by skin traction from the transverse bar of a Gallows from (Gallows traction). The buttocks are kept just clear of the bed so that their weight acts as the counter-traction .The fracture united in about a month.



**Fig. (26): Gallows traction.**



**2. Treatment of fractured shaft of the femur in children and adolescents:** Reduction and fixed skin traction on Thomas splint. Anatomical apposition is not essential, but correct alignment. Angulation, particularly varus or valgus must be corrected. A small amount of shortening up to half an inch can be allowed and is usually compensated by growth. After about six weeks, enough callus usually forms to hold the fragments together. A plaster hip spica can be applied for further period of one month.

**3. Treatment of fractured shaft of femur in adult:**

**First treatment:** The limb is pulled straight and a Thomas splint is applied with skin traction. Shock is treated.

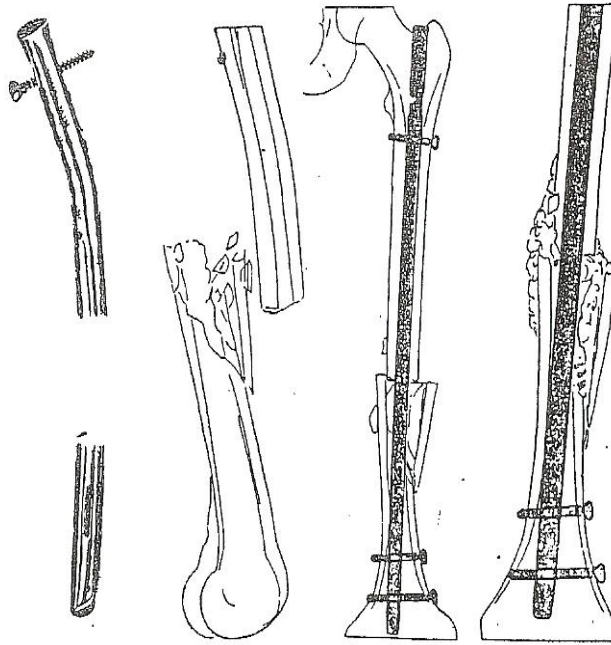
**A. Oblique and comminuted fractures:**

**Reduction and skeletal traction:** A Steinmann's pin is introduced transversely into the upper tibia behind the tibial tuberosity and a Thomas splint is applied.

**After care:** Quadriceps and foot exercises are taught and practised from the start. After three weeks may need to be diminished. After about 6 weeks, enough callus is usually formed at the site of the fracture to prevent shortening. However, traction is maintained for another 6 weeks to prevent angulation.

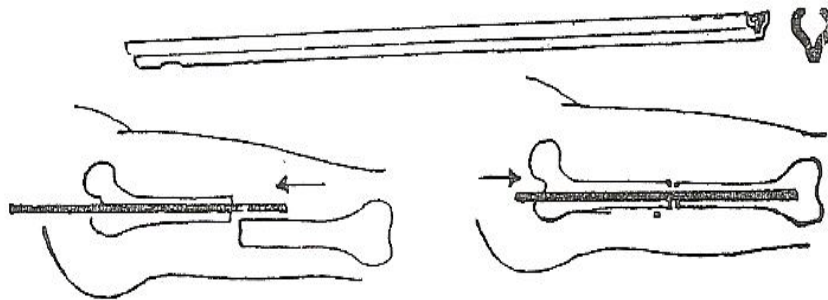
**B. Transverse fractures:**

Open reduction and intramedullar nail. It is essential to have a set of nails of proper length but of different diameter before starting, the operation. Intramedullary nail is not without danger. In particular, infection is a serious complication.



locked intramedullary nail. Note perforations at the ends of the nail that allow the insertion of transverse locking screws. Such type of nail secures sound fixation for fractures not suitable for conventional nailing.

Fig. (28): Locked Intramedullary nail.



Intramedullary nailing of the femur. Kuntscher nail is clover-leaf in cross section. The nail is introduced in the proximal fragment and is hammered to emerge in the gluteal region. The fracture is reduced, and the nail is hammered into the distal fragment.

Fig. (27): Intramedullary nail (Kuntscher nail).

## 5. Fractures of the distal end of the femur

### Supracondylar fracture of the femur

The distal fragment is usually tilted backwards by the pull of the gastrocnemius muscle

#### Treatment:

Manipulative reduction and skeletal traction on Bohlers splint. Uncontrolled displacement is corrected by open reduction and internal fixation with a condylar plate.

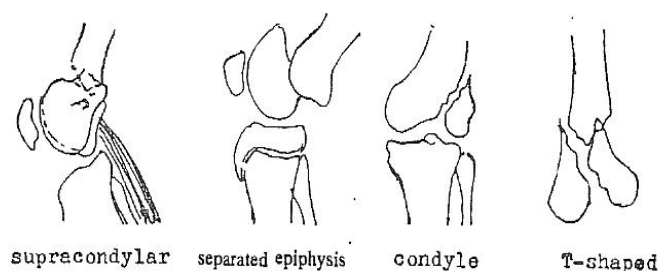


Fig. (29): Supracondylar fracture of the femur

## 6. Fracture of the leg bones

**Trauma:** Direct or indirect.

**Pathological anatomy:** Tibia is the commonest major long bone to be fractured. Being subcutaneous, it is commonly an open fracture. The fracture line may be transverse, oblique, spiral, comminuted or may be double level fracture.

**Clinically:** There is immediate disability after trauma. All signs of fracture are present. The circulation of the foot must be carefully examined.

#### Treatment:

Varies with the type of the fracture:

A. **Undisplaced fracture:** Common in children .The leg is splinted in an above knee plaster cast with the knee slightly bent. Weight bearing in plaster is allowed after about three weeks while the fracture unites.

## **B. Displaced transverse fractures:**

**Reduction:** The fracture is reduced by manipulation under general anaesthesia.

**Fixation:** A padded plaster is applied from the toes to the tibial tuberosity.

**Operative treatment:** Fractures, which prove impossible to reduce or are unstable after reduction should be treated by open reduction and internal fixation with plate and screws.

## **C. Displaced oblique and spiral fractures:**

Open reduction and internal fixation, as fracture is unstable and tend to redisplace if fixed in plaster.

## **D. Double level and comminuted fractures:**

It is dangerous to attempt open reduction and internal fixation in these cases as it damage periosteum. The alignment of the leg should be restored by manipulation and the position maintained in plaster. Union is often slow and should be anticipated. Bone grafting is needed if the fracture is not clinically united after 3-4 months.

# **7. Ligamentous injuries of the ankle**

**Patient:** Adult.

**Trauma:** Twisting of the foot.

**Pathological anatomy:** An inversion twist of the foot is a frequent injury, which results in a sprain or tear of the lateral ligament of the ankle. Injury of the deltoid ligament by eversion twist of the foot is rare.

**Clinically:** There is tenderness and swelling anterior and below the lateral malleolus. Pain is made worse by inversion of the foot.

**Treatment:**

**Sprained ankle:** The sprained ligament is infiltrated with novocaine 1% and 5 mg hydrocortisone and elastoplast strapping of the ankle is done. The patient is encouraged to resume his activities.

**Torn ligaments:** A below knee plaster cast is applied for six weeks. An elastoplast bandage is then applied for one month.

## **Physical Therapy and fractures**

Physical Therapy for fractures can be divided into management during immobilization and then after removal of fixation. The physical therapist must be careful to avoid anything that might delay repair or lead to non-union. Thus it is essential that the principles of fractures are understood and care should be taken for any particular precautions and complications.

### **1) Physical therapy during immobilization**

**The aims during this period are:**

1. Reduce edema: It is very important to do this as early as possible to prevent adhesion formation, and to decrease pain.
2. Assist the maintenance of the circulation to the area.
3. Maintain muscle function by active or static muscle contractions
4. Maintain joint ROM
5. Maintain function as allowed by the fracture and the fixation.
6. Teach the patient to use crutches, sticks, frames.

Assessment of the patient is essential in order to decide on the treatment required. It is not always necessary to treat a patient throughout this stage provided that the patient can be taught to do his own exercises. The patient must understand what is required and be motivated to carry it out. The physical therapist is responsible for monitoring the patient through this stage. If it is necessary to continue treatment this may be in the ward for an inpatient but outpatients may either be treated in a physiotherapy department or at home. Good treatment at this stage may prevent some of the problems that can occur when the fixation is removed.

### **Patient problems and physical therapy techniques**

Swelling should be reduced by elevating the limb and by active or static contractions of muscles thus minimizing the formation of adhesions and consequent stiff joints.

Active exercises by static or isotonic muscle activity will help to maintain a good blood supply to the soft tissues and aid in the reduction of swelling and prevent the formation of adhesions.

Muscles that cannot produce movement of a joint because of the fixation and do not work statically will waste very rapidly. Isometric or isotonic contractions performed correctly and repeated often enough will prevent excessive wasting.

Encouraging functional activity when possible also helps reduce the rehabilitation time after removal of fixation.

Patients must understand the importance of their treatment and physiotherapists must understand the problems and requirements of each patient.

## **2) Physical therapy after the removal of fixation**

Assessment of the patient should be carried out to formulate a plan of treatment.

Factors to be considered during evaluation:

1. Although certain clinical features can be expected after a particular fracture they will appear in different degrees in each patient and in some cases may not be present.
2. Every patient presents different problems apart from the injury and these may relate to age, family, work, leisure and the psychological reactions of the individual. These factors must be taken into account in planning a program of treatment and evaluating progress.

### **Aims of treatment:**

1. To reduce any swelling.
2. To regain full range of joint movement.
3. To regain full muscle power.
4. To re-educate full function.

### **1) Swelling**

Swelling should not be a great problem if exercises and general activities have been carried out during the immobilization period. It may be a problem in the lower limb if the muscles are very weak and there is a loss of joint range as both factors will prevent an adequate pumping action on the veins. Any edema must be reduced as quickly as possible as this will hinder active movement and lead to the formation of adhesions thus extending the rehabilitation period.

### **2) Range of joint movement**

Before attempting to regain any decreased range of movement the reason for the loss of range should be determined. It could be due to pain,

edema, adhesions or weak muscles. If there has been disruption of joint surfaces this may prevent a return to full range.

### **3) Muscle power**

The building of muscle power will depend on gaining maximal activity of the muscles and using them in all actions as prime mover, antagonist, fixator and associated movements with other muscle groups.

### **4) Full function**

In the majority of cases it should be possible to regain full function but if not it is important to gain the optimum function, and the extent of this will depend on the complications preventing full recovery. Planning must also take into account the needs of the patient in relation to home, work and leisure. In preparing a patient to return to work it is important to understand that the patient may have to work all day and know what type of work is involved-heavy laboring, industrial work on a production bench requiring repetitive movements of the hand or foot or both, or office work which can require a variety of different activities. Similarly home and leisure activities must be considered so that the patient is fully rehabilitated.

### **Physical therapy techniques**

- These are given and must be carefully selected following the assessment of the patient.
- The physical therapist must evaluate each treatment and change the techniques as required.
- Treatment should be gradually intensive, particularly in the final stages of rehabilitation, but always within the capability of the patient.
- Select the appropriate techniques and decide how they should be carried out. For example, with movement techniques judge carefully how many times each exercise should be performed and whether assistance or resistance is required.

## **Physical therapy for the common post-traumatic complications**

### **1) Myositis Ossificans**

**Definition:** The terms myositis ossificans and heterotopic or ectopic bone formation are often used interchangeably to describe the formation of bone in atypical locations of the body. Sometimes the term myositis ossificans is used to denote only ossification of muscle. More often, the term is used generally to characterize heterotopic bone formation in muscle-tendon unit, capsule, or ligamentous structures.

#### **Etiology**

Although myositis ossificans is not a common phenomenon, the sites most frequently involved are the elbow region and thigh. In the elbow, heterotopic bone formation most often develops in the brachialis muscle or joint capsule as the result of trauma, such as a comminuted fracture of the radial head, posterior elbow dislocation, a fracture dislocation (supracondylar or radial head fracture) of the elbow, or a tear of the brachialis tendon. Patients with neurological impairments, specifically traumatic brain injury or spinal cord injury, as well as patients with burns to the extremities are also prone to develop this complication. It may also develop as the result of aggressive stretching of the elbow flexors after injury and a period of immobilization. When the brachialis muscle is injured, ossification of the injured tissue is a potential complication.

#### **Symptoms**

Palpation of the distal brachialis muscle is tender. After the acute inflammatory period, heterotopic bone formation is laid down in muscle, between, not within, individual muscle fibers or around the joint capsule within a 2 to 4 week period of time, this makes the muscle extremely firm to touch.

#### **Prognosis**

Although myositis ossificans can permanently restrict elbow motion, in most cases, the heterotopic bone to a large extent is reabsorbed over several months, and motion usually returns to near normal.



## **Management**

**Contraindications:** Massage, passive movement, passive stretching, and resistive exercise are contraindicated if the brachialis muscle is implicated after trauma.

**Conservative treatment:** The elbow should be kept at rest in a splint, which should be removed only periodically during the day for active, pain-free ROM. Rest should continue until the bony mass matures and then resorbs.

**Surgical treatment:** Surgical excision of heterotopic bone from the muscle or a total elbow arthroplasty, if the capsule is also involved, is necessary only in rare instances.

## **2) Volkmann's ischemic contracture**

**Definition:** It is a massive infarction, mainly on the muscles and to a lesser degree on the other soft tissues.

### **Causes**

It is the result of a compartment syndrome. Compartment syndromes result when increased pressure within limited anatomic space compromises circulation to surrounding tissues. It is common after paediatric supracondylar humerus fracture treated with long arm cast with elbow placed in extreme flexion.

### **Pathology**

The lesion is a massive infarct, mainly on the muscles and to a lesser degree on the other tissues. It varies in length from a few centimetres, to the full length of the forearm. The severity of damage varies from mild fibrosis to total necrosis. The flexors are more affected than the extensors. The deep muscles of the forearm, the flexor digitorum profundus and flexor pollicis longus are more affected than the superficial muscles. Fibrosed muscles lead to contracture and deformity. The median nerve is liable to ischemia more than the ulnar nerve.

## **Clinical Picture**

- 1- Deformity: Flexion of the wrist and interphalangeal joints, with extension of the metacarpo-phalangeal joints.
- 2- Contracture: The flexors of the fingers are short. When the wrist is flexed, the fingers can be passively extended; when the wrist is extended, the fingers become flexed and cannot be passively extended.
- 3- Atrophy: The forearm muscles become atrophied.
- 4- Ischemic neuritis: Sensory loss along the distribution of the median nerve.
- 5- Trophic changes in the fingers are often present.

## **Prevention**

- Early reduction of the fractures around the elbow to relieve any pressure of the brachial artery.
- Position of fixation of supracondylar fracture should be in full elbow extension with the forearm supinated.
- Avoid tight bandage.
- Early treatment at the onset of ischaemia.

## **Treatment**

- A) Non operative treatment:     Stretching of the contracture on a splint.
- B) Operative treatment followed by physical exercises to regain the ROM and muscle power as much as possible.

## **3) Shoulder-Hand syndrome (reflex sympathetic dystrophy)**

**Definition:** It is a painful shoulder with limited movement and symptoms of swelling, pain, stiffness, sweating, and color changes of the hand.

## **Causes**

- Myocardial infarction.
- Post-hemiplegia.
- Post-traumatic.
- Post-herpetic.
- Secondary to:
  - Cervical diskogenic disease or
  - Shoulder pericapsulitis.

### **Clinical picture**

- 1- Circulatory impairment of the venous and lymphatic systems in the arm and hand.
- 2- Limitation of shoulder movements.
- 3- Edema and contracted collateral ligaments leading to limitation of metacarpo-phalangeal joints.
- 4- Restriction of wrist movement and it is maintained in a flexed position.
- 5- There may be involvement of the sympathetic nervous system leading to:
  - Pain and swelling in the hand.
  - Trophic skin changes.
  - Vasomotor changes.
  - Pain and limited ROM of the shoulder.

### **Management**

This is a progressive disorder unless vigorous intervention is used. Treatment consists of:

- a) Encouraged motion of the hand and shoulder in spite of pain which increases with movement. Future immobilization leads to increased stiffness, contracture and atrophy of skin, bone and muscles.
- b) Sympathetic procaine blocks.
- c) Procaine and cortisone injections into the shoulder and trigger pain points.

#### **d) Physical therapy management:**

- 1- Paraffin baths to the hands.
- 2- Increase limited ROM of the shoulder and hand by using:
  - Joint mobilization technique.
  - Muscle elongation and stretching.
  - Soft-tissue stretching.
- 3- Increase the activity of the upper limb through:
  - (a) Isotonic exercises and
  - (b) Functional activities.
- 4- Elevate and wrap the extremity if there is edema.
- 5- Educate the patient the importance of the program of increased activity.

### **Prevention**

Prevention is the best therapy, whenever there is shoulder involvement or referred pain to the shoulder, the entire upper extremity should be moved as soon as allowed, at a safe intensity for the condition.